



National rectal cancer intensity-modulated radiotherapy (IMRT) guidance

January 2021

Contents

Foreword	3
1. Introduction	4
2. Pre-radiotherapy investigations	4
3. Indications for radical radiotherapy in rectal cancer	5
Short-course radiotherapy (SRCT)	5
Long-course (chemo)radiotherapy	5
Additional indications	5
4. Therapeutic schema	5
Dose prescription SCRT	5
Dose prescription preoperative LCRT	5
Dose prescription in adjuvant LCRT	5
Concurrent chemoradiotherapy	5
5. Pre-treatment	5
Target volumes	6
Gross tumour volume (GTV)	6
Internal clinical volume (ICTV)	7
Planning target volumes	9
OARs	10
6. Treatment technique and dose calculation	11
7. Dose prescription, target objectives and OAR dose constraints	12
Target objectives	12
Dose constraints for long-course radiotherapy	13
Dose constraints for short-course radiotherapy	14
8. Treatment verification	14
Appendix 1. Suggested rectal filling protocol	16
Appendix 2. Volume definitions	17
Appendix 3. Table detailing ICTV_Elec nodal compartment borders	18
Appendix 4. Step-by-step description of how to create ICTV_Elec	20
Appendix 5. Use of bowel cavity	24
Appendix 6. On-treatment CBCT image troubleshooting	26
Appendix 7. Contributors	31

Foreword

The true benefits of advanced radiotherapy techniques will only be realised if they are adopted widely and safely. This practical guidance document is a huge step towards achieving this for people with rectal tumours. It provides a clear and logical approach to patient preparation, contouring and delivery of radiotherapy which should become the national standard for all patients.

We would like to thank the clinicians who have drafted and re-drafted the guidance and commend all radiotherapy departments to ensure that it is used as a basis for ensuring quality for every patient in the UK treated with this technique.

Dr Rebecca Muirhead

On behalf of the Rectal IMRT National Guidance Working Group

Dr Tom Roques

Medical Director, Professional Practice Clinical Oncology, RCR

1. Introduction

The role of radiotherapy in the treatment of locally advanced rectal cancer has been definitively established, with evidence demonstrating that patients who undergo preoperative radiotherapy have a significant reduction in their risk of loco-regional recurrence.¹⁻⁵ The current standard of care for locally advanced rectal cancer is therefore (chemo)radiotherapy followed by total mesorectal excision (TME). Indications for the delivery of preoperative radiotherapy include reducing the risks of local recurrence in operable and margin-threatening disease, increasing the rates of R0 resection in margin-threatened disease and improving symptom control and disease-specific survival in inoperable disease. Additional indications for radical radiotherapy in rectal cancer include single-modality treatment for organ preservation and postoperative radiotherapy in the setting of an unexpected R1/R2 resection.

The use of intensity-modulated radiotherapy (IMRT) for rectal cancer is increasing within the United Kingdom and internationally. Consensus guidelines for IMRT in rectal cancer are required to address the multiple considerations when implementing the introduction of routine IMRT. These include considerations for pre-treatment investigations, patient preparation, optimal delineation of gross tumour volume (GTV)/clinical target volume (CTV)/planning target volume (PTV), provision of a standard atlas for delineation of lymph nodes, strategies for delivery of a simultaneous integrated boost (SIB), IMRT planning and patient set-up and treatment verification.⁶

This document presents an evidence-based consensus guideline for the use of IMRT/volumetric modulated arc therapy (VMAT) for rectal cancer in the UK. The guidance illustrates the consensus reached among the authors and collaborative groups. This document provides guidance for IMRT treatment in rectal cancer and therefore the interpretation, local implementation and use remains the responsibility of the treating clinician.

2. Pre-radiotherapy investigations

- History and clinical examination including documentation of patient performance status. Consider digital rectal examination of low rectal tumours
- Biopsy confirmed adenocarcinoma
- Magnetic resonance imaging (MRI) of the pelvis (dedicated rectal protocol)
- Contrast-enhanced computed tomography (CT) of the chest/abdomen/pelvis
- Colonoscopy or CT colonography
- Baseline bloods including baseline carcinoembryonic antigen (CEA)
- Details of examination under anaesthetic if performed
- Whole-body ¹⁸F-fluorodeoxyglucose (FDG) positron emission tomography-computed tomography (PET-CT) in selected cases following multidisciplinary team (MDT) discussion

Indications for de-functioning stoma

1. Patients with significant faecal urgency or incontinence which may compromise their ability to complete planned treatment
2. Patients with symptoms of obstruction and/or signs of obstruction on imaging or at scope
3. Patients with rectovaginal or rectovesical fistula from tumour.

3. Indications for radical radiotherapy in rectal cancer

Short-course radiotherapy (SCRT)

1. Preoperative SCRT to reduce local relapse rate
2. SCRT for local control

Long-course (chemo)radiotherapy (LCRT)

1. Preoperative LCRT to reduce local relapse rate
2. Adjuvant postoperative LCRT

Additional indications

The same protocol can apply in other selected radical and palliative settings or as part of a clinical trial; this is at the discretion of the treating clinician.

4. Therapeutic schema

Dose prescription SCRT

- 25 Gray (Gy) in 5 fractions, (5 Gy/#) in 5–7 days

Dose prescription preoperative LCRT

- Dose to elective target volume = 45 Gy in 25 fractions (1.8 Gy/#) in 5 weeks*
- Optional dose to gross disease for simultaneous integrated boost (SIB) = 50 Gy in 25 fractions (2 Gy/#) in 5 weeks

*Dose response data correlates with complete response rather than local relapse.⁷ As such, an SIB of >50 Gy should only be considered in this setting, for example, organ preservation, postoperative with residual macroscopic disease or disease outside the resection margin. 52 Gy in 25 fractions is an equivalent dose to the 54 Gy in 30 fractions used in the EXPERT trial and reported minimal acute toxicity in a small series.^{8,9}

Dose prescription in adjuvant LCRT

- Elective and postoperative bed = 45 Gy in 25 fractions (1.8 Gy/#) in 5 weeks
- If residual macroscopic disease is present or R1 resection has been performed and the site of R1 can be identified by clips or landmarks, consider SIB.

Concurrent chemotherapy

In patients receiving LCRT, concurrent chemotherapy should be delivered unless there are contraindications or concerns regarding their ability to tolerate treatment. Dose reductions due to patient co-morbidities, dihydropyrimidine dehydrogenase (DPD) status, performance status and/or age are at the discretion of the treating team.

5. Pre-treatment

- Standard position: supine with immobilisation for popliteal fossa and feet. Although there is dosimetric benefit of prone position with belly board, gastrointestinal (GI) toxicity with IMRT is low and patients are less stable in a prone position, therefore it is recommended that patients are treated supine.

- All patients must be scanned with a comfortably full bladder (>250 ml) using the local bladder filling protocol.
- The use of intravenous (IV) contrast to aid delineation of pelvic vessels and GTV is recommended.
- Placement of a radio-opaque marker can be considered as a reference point especially for low rectal cancers.
- Oral contrast can be used to aid with delineation of small bowel loops.
- Patient should be scanned from superior aspect of L2/3 to 4 cm below the lesser trochanters.
- The recommended slice thickness is 2–3 mm.
- Tattoo and document as per local protocol.
- Optional rectal filling protocol is considered in [Appendix 1. Suggested rectal filling protocol](#).

Target volumes

[Appendix 2. Volume definitions](#) lists all the volume definitions.

Clinicians should refer to the diagnostic imaging (MRI pelvis and CT thorax, abdomen and pelvis), clinical examination and endoscopic findings. If possible, the diagnostic or planning MRI can be fused with the planning CT. The treating consultant oncologist should review and approve the registration. Radiologist support may be helpful in determining the GTV. Peer review for delineation quality assurance is strongly recommended.¹⁰

There will be challenging cases for which these guidelines are not appropriate or require adaptation. For example, in adjuvant radiotherapy it may be appropriate to target a surgical bed alone, incorporate elective nodes or boost residual disease, depending on the type of surgery and extent of resection. In low tumours with involved external iliac or inguinal nodes, elective nodes may need to include these nodal compartments. These guidelines do not cover complex cases which will require thorough MDT discussion and peer review in advance of individualised adaption of the guidelines.

Gross tumour volume (GTV)

GTVp	Macroscopic primary tumour, areas of adjacent extramural vascular invasion or postoperative macroscopic disease identified on imaging.
GTVn	All nodes involved with tumour.

Optional GTV volumes

GTVp_Boost	The areas of GTVp the clinician wishes to boost (which may be identical to the GTVp).
GTVn_Boost	All the areas of GTVn the clinician wishes to boost (which may be identical to the GTVn).

- GTVp should include the macroscopic primary tumour, areas of extramural vascular invasion (see Figure 1) or areas of residual macroscopic disease seen on postoperative imaging. If the tumour can be confidently identified, the GTVp can include macroscopic disease only, without the whole lumen. In this situation, lumen, rectal gas or faecal contents should not be included in the volume. However, it is recognised that there will be cases where it is not possible to confidently delineate the tumour alone. In these cases, the whole lumen can be included.

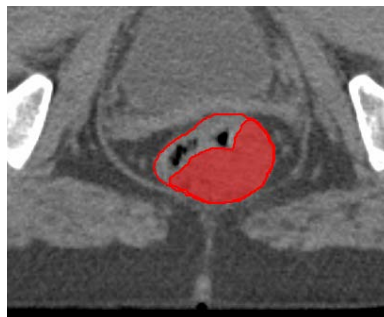

Figure 1. Axial CT image showing GTVp (red fill). The red outline of the whole circumference including normal rectum is only used if there is clinical uncertainty of delineating the GTV.

- GTVn is all involved nodes. Involved lymph nodes are defined by the local MDT using all available imaging.
- The GTVp_Boost is the areas of tumour that would benefit from a boost. The indication and rationale for doing this will vary on an individual patient basis depending on, for example, the extent of disease, planned extent of surgery or whether further treatment will be delivered. As such, this is at the discretion of the treating clinician.
- The GTVn_Boost is the area of nodes that would benefit from a boost. As above, this will differ in each case and will be at the discretion of the treating clinician.

Internal clinical target volume (ICTV)

ICTV is a CTV that includes a margin for motion according to the American Association of Physicists in Medicine (AAPM) and the International Commission on Radiation Units and Measurements (ICRU).^{11,12}

Required in all cases

ICTVp (primary ICTV)	GTVp + 10 mm in all directions except anteriorly where 15 mm can be considered for tumours that may be more mobile anteriorly (eg, upper rectal tumours above the peritoneal reflection).
ICTVn (any grossly involved nodes)	GTVn + 5 mm in all directions.
ICTV_elec	All elective nodal groups combined.
ICTV_final	ICTVp + ICTVn + ICTVsb (if present) + ICTV_Elec

Required in selected cases

ICTVp_Boost	GTVp_Boost + 10mm in all directions except anteriorly where 15 mm can be considered for tumours that may be more mobile anteriorly (eg, upper rectal tumours).
ICTVn_Boost	GTVn_Boost + 5 mm in all directions.
ICTVsb	Area around surgical bed at risk for microscopic disease (for postoperative radiotherapy only).
ICTV_high	ICTVp_Boost + ICTVn_Boost

- ICTVp is GTVp with a margin for microscopic disease and motion. While there is some literature on the motion of primary tumours, there is limited literature on microscopic disease spread hence these are pragmatic margins which are likely to cover both these uncertainties and be usable in clinical practice. ICTVp should be edited off bone in all directions other than posteriorly towards the sacrum and edited off muscles unless there are obturator nodes, in which case the obturator internus muscle should be included on that side.
- ICTVn is GTVn with a margin for microscopic disease and motion. Although mesorectal nodes may move more than 5 mm, to limit the complexity of the guidelines and due to the fall-off dose that will be present in practice, a 5 mm margin is suggested. ICTVn should be edited off bone in all directions other than posteriorly towards the sacrum and edited off muscles unless there are obturator nodes, in which case the obturator internus muscle should be included on that side.
- ICTV_elec covers all elective nodal groups. This volume should always include the nodal compartments of: mesorectum, presacral, obturator nodes and internal iliac nodes.
 - The ICTV_Elec includes a 1 cm margin anterior to the mesorectum to incorporate the motion of the anterior border of the mesorectum as the bladder reduces in size over the treatment in LCRT.
 - If neo-adjuvant chemotherapy has been used, the ICTV_Elec must cover all compartments that contained nodal disease at the outset. Where there was previously disease, superiorly the ICTV_Elec should be 2 cm above the most superior node at outset.
 - If there is radiological evidence suggestive of nodal involvement in any nodal compartment, other than those outlined above (for example, external iliac node or inguinal node) or in the ischiorectal fossa, these complex cases should be discussed at a multidisciplinary team meeting (MDTM). If radiotherapy is planned to these nodes, the entire compartment should also be included. For guidance on delineation of ischiorectal fossa, inguinal nodes or external iliac nodal compartments see anal cancer guidance.¹³
 - **Appendix 3. Table detailing ICTV_Elec nodal compartment borders** – highlighting the borders of these nodal compartments.
 - **Appendix 4. Step-by-step description of how to create ICTV_Elec** – includes step-by-step instructions on creating an ICTV_Elec.

- ICTV_Final is the combination of ICTV_p, ICTV_n and ICTV_Elec.
- ICTV_p_Boost is GTV_p_Boost with a margin for microscopic disease and motion.
- ICTV_n_Boost is GTN_n_Boost with a margin for microscopic disease and motion.
- ICTV_{sb} is only relevant when treating patients with post-operative radiotherapy. This should include all areas of potential microscopic disease post-operatively, using surgical clips if present. It should cover all areas of disease present on preoperative imaging. These complex cases will likely require thorough MDT discussion before making decisions on target volumes.
- ICTV_High is the area for boosting including a margin for microscopic disease and movement.

Planning target volumes (PTV)

The exact PTV margins used will depend on the centre-specific set-up error but the minimum recommended CTV-PTV margins are outlined below. As shown, two possible margins are suggested for those using two different verification protocols (for example, use of daily imaging versus no daily online imaging). Note that none of the margins below incorporate outlining uncertainties.

With daily online volumetric imaging

PTV (In patients with one dose level only)	ICTV_Final + 5 mm in all directions.
PTV_High	ICTV_High + 5mm in all directions.
PTV_Low (Elective dose level for patients treated with SIB)	ICTV_Final + 5 mm in all directions.

With offline imaging (verification protocol that does not include daily online imaging)

PTV (In patients with one dose level only)	ICTV_Final + 10 mm in all directions.
PTV_High	ICTV_High + 10 mm in all directions.
PTV_Low (Elective dose level for patients treated with SIB)	ICTV_Final + 10 mm in all directions.

Organs at risk (OARs)

The use of bowel loops is recommended due to the Radiation Therapy Oncology Group (RTOG) guidance and the evidence base correlating toxicity and constraints.^{14,15} In addition, loops will likely be used in future clinical trials of biological agents and dose escalation.

Should centres be unable to delineate bowel loops, details of delineation and constraints for bowel cavity are available in [Appendix 5. Use of bowel cavity](#).

Organ	Standardised treatment planning system (TPS) name	Definition	Main reference
Small bowel loops	Bowel_Small	Contouring should include all individual small bowel loops to at least 20 mm above the superior extent of both PTVs. It may be helpful to initially delineate the large bowel +/- endometrium to exclude these from subsequent delineation of small bowel.	14
Bladder	Bladder	Contour outer wall of bladder, inferiorly from its base and superiorly to the dome.	14
Right and left proximal femurs*	Femur_Head_R Femur_Head_L	Contour femoral ball, neck, greater and lesser trochanters and proximal femoral shaft as a single structure. Superiorly, cranial edge of femoral ball; inferiorly, caudal aspect of lesser trochanter. <i>Tips: Auto-contouring threshold parameters with bone can facilitate this process but requires editing any auto-contouring artefacts.</i>	14

*Not required in short-course radiotherapy.

Optional in low rectal cancer treated with LCRT

Organ	Standardised treatment planning system (TPS) name	Definition	Main reference
External genitalia – female/male	Female_genitalia Male_genitalia	Delineation of the male genitalia should include the penis and scrotum. In a woman, it should include the clitoris, labia majora and minora. The lateral extent of the volume is the inguinal creases. Cranially this will extend to the level of the mid symphysis pubis. <i>Note: this structure is optional in low rectal cancers including the anus or individuals with external iliac or inguinal nodes at risk of toxicity.</i>	13

6. Treatment technique and dose calculation

Static coplanar beam IMRT, VMAT and TomoTherapy are all acceptable treatment techniques, although VMAT allows for considerably faster treatment delivery (10–15 minutes for IMRT versus 3–5 minutes for VMAT). Megavoltage beams should be used, with or without flattening filter, with recommended energies ≥ 6 megavolts (MV). Dose calculations should be performed on the basis of a three-dimensional (3D) scan, using a dose calculation matrix with ≤ 3 mm resolution. A modern dose-calculation algorithm taking tissue inhomogeneity and lateral electron transport into account (type B algorithm) must be used; examples include CCCS (Pinnacle), recent versions of AAA (Eclipse), CC (Oncentra), Acuros (Eclipse) or any Monte Carlo-based dose calculation engine. Scan artefacts, for example, from artificial hips, should be corrected for using standard local procedures. For patients with artificial hips, beam entry through the hips should be avoided. High-density contrast may be reassigned density, as may large volumes of air which are unlikely to be present at treatment delivery. For patients with defunctioning stomas, beam entry should, if possible, avoid the stoma. The stoma bag should be moved outside of the treatment fields if possible due to the day-to-day variation in filling and the risk of unintended bolus-effects.

For static-beam IMRT, five or seven fields (typically uniformly distributed) are sufficient to achieve good dose distributions. For supine patients, avoid 0° beams (entering through anterior OARs).

A number of different arc configurations can be used for VMAT. A full (360°) return arc provides acceptable dose distributions for most patients, as long as doses to OARs are actively minimised in the plan optimisation. For more challenging patient anatomies – especially patients with very concave target volumes including patients with external iliac or

inguinal node irradiation – splitting the arcs in two (see below) may increase the degrees of freedom in optimisation. In some treatment planning systems, creating anterior avoidance volumes or arc sectors may simplify OAR sparing. Alternatively, a beam arrangement which avoids anterior beam entry can provide robust plan solutions (Figure 2), for example, $60^{\circ} \rightarrow 180^{\circ}$ and $300^{\circ} \rightarrow 180^{\circ}$ return arcs for supine patients and $240^{\circ} \rightarrow 120^{\circ}$ returns arc for prone patients.

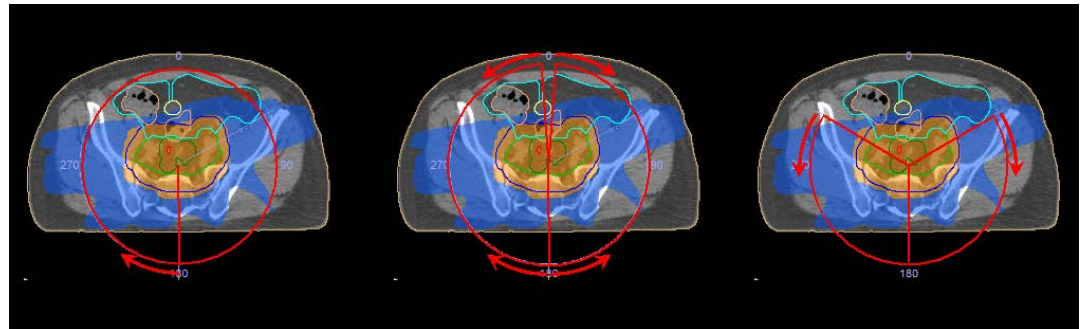


Figure 2. Potential arc arrangements for VMAT delivery. The single return arc arrangement (left) is sufficient for most patients but requires active optimisation to reduce the dose to anterior OARs. Split arc arrangement (centre) can be useful for complex cases. Partial arc arrangement (right) simplifies OAR sparing and is relatively robust to bowel OAR definition.

7. Dose prescription, target objectives and OAR dose constraints

Dose should be prescribed to the median target dose, in line with ICRU 83;¹² that is, the PTV should receive 100% of the prescription dose to 50% of the volume. For patients treated with SIB, the primary prescription is to the boost volume.

Dose to treatment target should always take precedence over OAR constraints using the following prioritisation:

1. PTV_Low/PTV
2. PTV_High
3. Bowel
4. Bladder
5. Femoral head
6. Genitalia

Target objectives

Volume	OAR/target	Optimal constraints
PTV_High	D99%	>90%
	D95%	>95%
	D50%	= 100% ± 2%
	D2%	<105%
PTV_Low/PTV	D99%	>90%
	D95%	>95%
	D50%	= 100% ± 2%
PTV_Low minus PTV_High + 5 mm	V107%	<15%

Dose constraints for long-course radiotherapy

Organ at risk	OAR/target	Objective	Mandatory constraint
Bowel Loops [‡]	D180cc	<35 Gy	
	D100cc	<40 Gy	
	D65cc	<45 Gy	
	D0.5cc	<52.5 Gy	<52.5 Gy
Femoral Heads*	D50%	<30 Gy	<45 Gy
	D35%	<40 Gy	<50 Gy
	D5%	<50 Gy	<52.5 Gy
Bladder*	D50%	<35 Gy	<45 Gy
	D35%	<40 Gy	<50 Gy
	D5%	<50 Gy	<52.5 Gy
Genitalia*	D50%	<20 Gy	<35 Gy
	D35%	<30 Gy	<40 Gy
	D5%	<40 Gy	<52.5 Gy

*Constraints from Anal cancer IMRT guidelines.¹³‡Constraints from RTOG 0822.¹⁶

Dose constraints for short-course radiotherapy

Organ at risk	OAR/target	Objective
Bowel Loops [§]	D200cc	<20 Gy
	D150cc	<22 Gy
	D20cc	<25 Gy
Bladder [§]	D45%	<21 Gy

[§]Based on in-house protocol from Glasgow.

No formal constraints for genitalia or femoral heads.

8. Treatment verification

Aim

The aim is to cover all relevant ICTV and GTV structures with the planned PTV, PTV_low and PTV_high daily. The prioritisation of structures should reflect that of the planning prioritisation (see previous section) that is, dose to target volume should always take precedence over OAR.

1. PTV_Low/PTV
2. PTV_High (if present)
3. Bowel, bladder, femoral heads, genitalia

On-treatment imaging (CBCT or paired kV images) should be used to:

- Localise treatment volumes (may be multiple targets with differential motion which should be evaluated independently) and verify treatment is as planned
- Correct for gross set-up errors including tilts/rotations in pelvic bony structures
- When CBCT is performed, assess changes in internal anatomy, for example, rectal and bladder filling which may impact on the dosimetric validity of treatment plan and escalate if necessary
- Evaluate local set-up uncertainties and margins.

Frequency

Online imaging using cone-beam CT (CBCT) should be performed to assess adequate coverage of all soft tissue ICTV.

In LCRT daily CBCT imaging is recommended and will allow for reduced margins. A minimum frequency of CBCT days 1–3 and weekly; or CBCT days 1–3 and weekly with kiloVoltage (kV) images on remaining days is required, as per *On target 2: updated guidance for image-guided radiotherapy*.¹⁷

- For SCRT, daily CBCT is required to ensure accurate and safe delivery.

Defining matching protocol

On-treatment matching protocols should be defined prospectively, that is, before the first treatment. By defining a matching protocol for each patient in advance, radiographers can become familiar with nomenclature, prioritise relevant CTV and PTV structures and reduce any confusion with other planning structures. Local training and competency should ensure staff groups responsible for treatment verification have the relevant knowledge and skills.

The region of interest (ROI) used in the matching process should be carefully selected. Radiographers should ensure the ROI used for automatic matching is representative of the relevant ICTV, PTV and OAR structures. High-contrast anatomy with differential motion to the targets should be excluded, for example, symphysis.

A visual check is necessary following automatic registration. Use of automated matching algorithms within user defined clipboxes/ROI can be a useful tool to aid target matching but the success of automated matching algorithms is dependent on the inclusion/exclusion of anatomical structures and at times they fail.

Target volumes may include structures with differential motion, for example, CTV nodes (ICTV_elect), GTV primary (GTVp) or pathologically involved nodes (GTVn). It is important to check these are all covered by the PTV, especially if a manual adjustment to the automatic registration has been performed.

Appendix 6. On-treatment CBCT image troubleshooting contains detailed guidance on the use of on-treatment CBCT for rectal cancer.

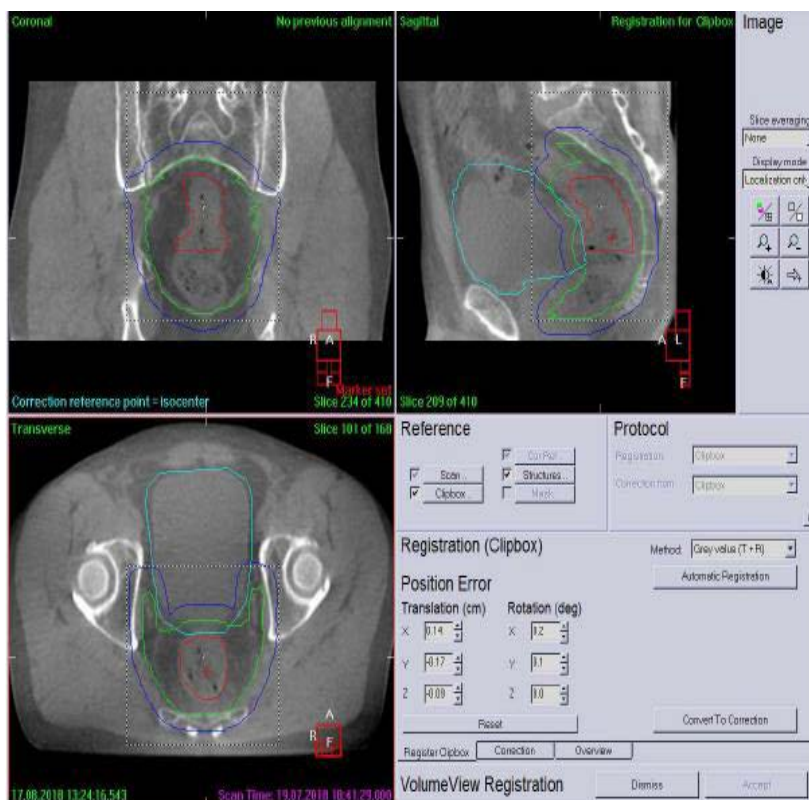


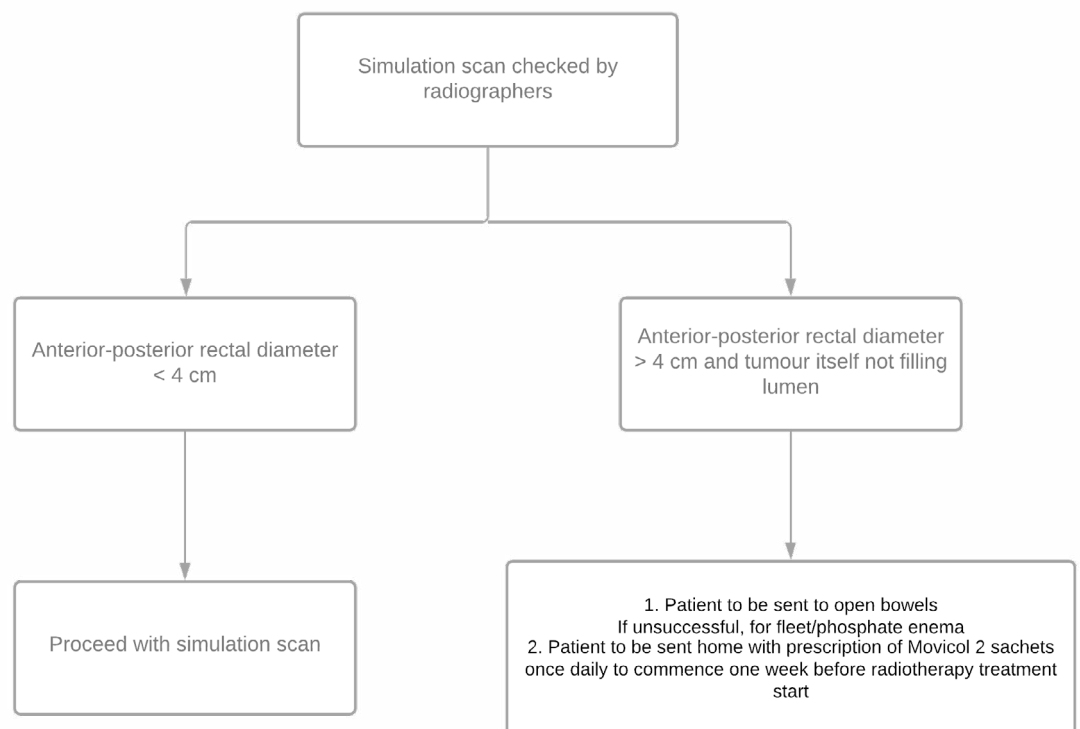
Figure 3: A cone-beam CT image demonstrating basic structures and illustrating the use of a large automated matching clipbox which covers the sacrum.

This document was approved by the Clinical Oncology Professional Support and Standards Board on 17 September 2020.

Appendix 1. Suggested rectal filling protocol

Ideally the rectum should be empty at planning as rectal volume decreases on treatment, particularly in smaller tumours prone to motion and in later weeks of LCRT. CT localiser radiographs can be useful for this purpose and should encompass the full extent of the intended scan. For example, an anteroposterior (AP) localiser can be used to identify areas of gas identified in the lower pelvis and a lateral topogram could be performed to measure the antero-posterior diameter of any rectal gas. CT scans should be reconstructed and the rectal diameter assessed. If it is >4 cm diameter, consideration should be given to either taking the patient off the scanner and asking them to empty their rectum or prescribing a phosphate enema. For larger symptomatic tumours, clinical judgement of adaption of this rectal filling protocol is required.

An example of a rectal assessment workflow, for patients treated to a PTV_High is provided below.



If the rectum is distended by flatus but is not congested with faecal matter, ask the patient if they are able to pass wind while in position on the scanner couch.

If the patient cannot pass wind while in the treatment position, the patient could be asked to try and relieve their gas. Sitting on the toilet can be effective in releasing gas.

Consideration of bladder filling as a result of delays in scanning: if there have been significant delays it is important that the bladder is not 'over-full'. Any deviations from bladder filling/standard departmental drinking protocol should be clearly documented to aid treatment reproducibility.

Appendix 2.
Volume definitions

Nomenclature is based on AAPM 263.¹¹ The following volumes should be delineated as appropriate:

Gross primary tumour volume	GTVp
Gross nodal tumour volume	GTVn
Gross primary tumour to be boosted	GTVp_Boost*
Gross nodal tumour to be boosted	GTVn_Boost*
Clinical target volume of the primary tumour volume including margin for motion	ICTVp
Clinical target volume of the nodal tumour volume including margin for motion	ICTVn
Clinical target volume of the areas of primary tumour volume for SIB including margin for motion	ICTVp_Boost*
Clinical target volume of the nodal tumour volume for SIB including margin for motion	ICTVn_Boost*
Clinical target volume of the surgical bed including margin for motion	ICTVsb
Clinical target volume of the elective nodal groups – CTV including margin for motion	ICTV_Elec*
Clinical target volume of the areas to be boosted including a margin for motion	ICTV_High*
Combined internal clinical target volume	ICTV_Final
Planning target volume when only one dose level is planned	PTV
High dose planning target volume in cases of planned SIB	PTV_High
Elective planning target volume in cases of SIB	PTV_Low
Bowel cavity	Spc_Bowel
Individual small bowel loops	Bowel_Loops*
Bladder	Bladder
Left femoral head	Femur_Head_R
Right femoral head	Femur_Head_L
Genitalia (only in low rectal cancer involving the anus)	Genitalia

*Not within AAPM263 guidance as these are not defined in that document.¹¹

Appendix 3. Table detailing ICTV_Elec nodal compartment borders

	Superior	Inferior	Lateral	Medial	Anterior	Posterior
Presacral nodes	Anterior border of the S1/2 junction*, or 2 cm above the highest superior involved node (including those present prior to neo-adjuvant chemo).	Caudal border of the mesorectum	Sacroiliac joints		10 mm anterior to the anterior aspect of the vertebrae or sacrum or 7 mm anterior to the superior rectal artery or inferior mesenteric artery, whichever is more anterior.	Anterior wall of the vertebrae. Include the sacral nerve root notch, exclude iliopsoas.
Mesorectal nodes	Either the anterior border of the S2/3 junction or, if it can be identified, the bifurcation of the inferior mesorectal artery into the superior mesorectal artery and the sigmoid artery.	Insertion of the levator ani muscle into the external sphincter muscles (disappearing of the mesorectal fat around the rectum). The inferior border should be 2 cm below the inferior GTVp slice, therefore if appropriate continue the ICTV_Elec into the anal canal.		Upper/mid: Mesorectal fascia if visible or medial border of the internal iliac nodes/obturator nodes. Lower: lateral edge of levator ani muscle.	Superior: 7 mm anterior to the superior rectal artery or inferior mesorectal artery. This may match with 1 cm presacral anterior margin at S1/2. Mid/inferior: 1 cm anterior to the mesorectal fascia.	Anterior surface of the sacrum and coccyx to the level of ischio-rectal fossae (including the medial part of the presacral space).

	Superior	Inferior	Lateral	Medial	Anterior	Posterior
Internal iliac nodes	Anterior border of the S1/2 junction*, or 2 cm above the highest superior involved node (including those present prior to neo-adjuvant chemo).	Superior border of the obturator nodes at the most superior part demonstrating the obturator internus.	7 mm lateral to internal iliac vessels excluding normal anatomical structures (eg, Iliopsoas muscle).	In the upper pelvis, 7 mm medial to internal iliac vessels.	Upper: 7 mm anterior to the internal iliac vessels, excluding normal anatomic structures. Mid/lower: Mesorectal fascia, pelvic organs.	Sacro-iliac bone, Piriformis muscle or Pre-sacral nodal volume.
Obturator nodes	At the most superior slice demonstrating the obturator internus, the inferior border of the internal iliac nodes.	At the point the obturator artery exits the pelvis. This is identified by the obturator artery moving lateral to the obturator internus.	The obturator internus muscle (unless there are pelvic side-wall nodes where the bony sidewall should be used).	Anterior: 17 mm from obturator internus muscle, include areas of bladder if present. Posterior: The mesorectal volume.	The anterior extent of the obturator internus muscle.	The sacroiliac joint or the piriformis.

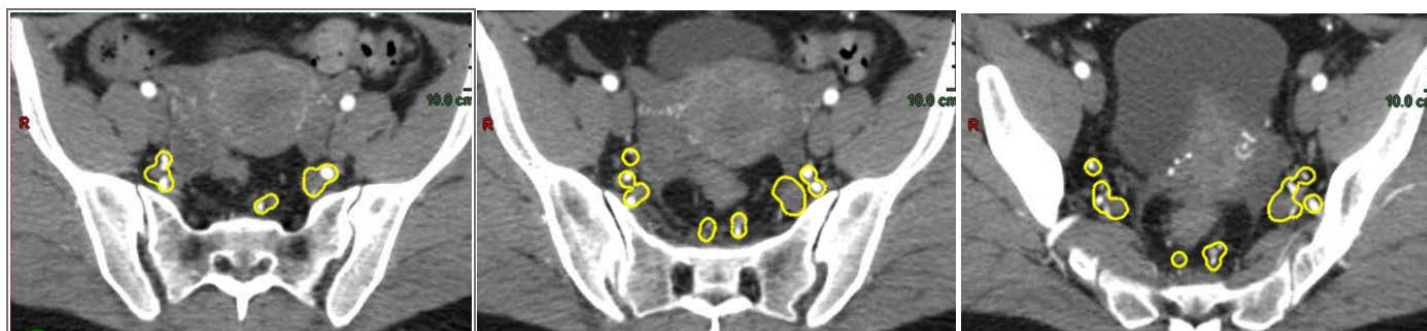***NOTE** The superior border of the ICTV_Elective is higher than in the ARISTOTLE trial.¹⁸ This was reduced due to concerns about bowel toxicity with the combination of Irinotecan in that trial but until relapse data is available it is suggested that the superior border S1/2 is kept the same. In selected low tumours this can be reduced at the clinician's discretion. In the Dutch TME trial, 15% of the population had a lower superior border than S1/2.³

Appendix 4. Step-by-step description of how to create ICTV_Elec

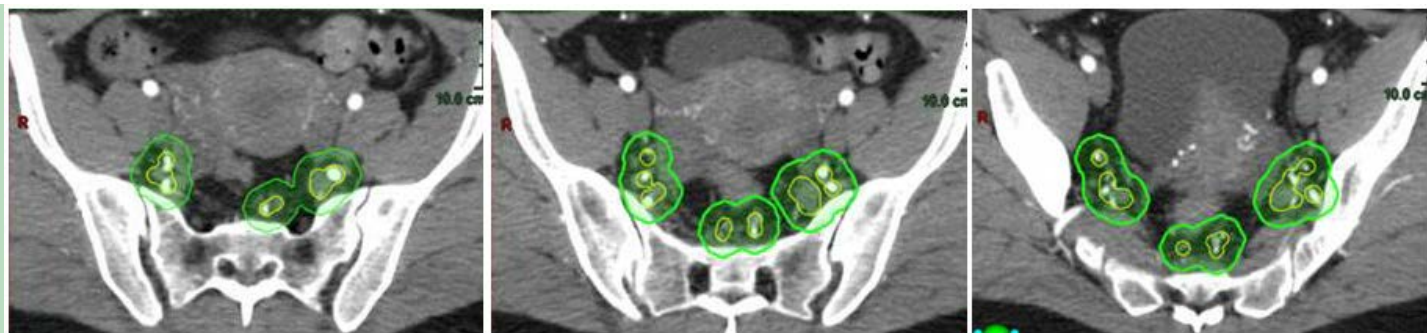
ICTV_Elec includes the nodal groups: internal Iliac, obturator, pre-sacral, mesorectal and obturator nodes. The nodes surrounding the inferior mesenteric artery and superior rectal artery are also included.

Internal iliac and presacral nodes

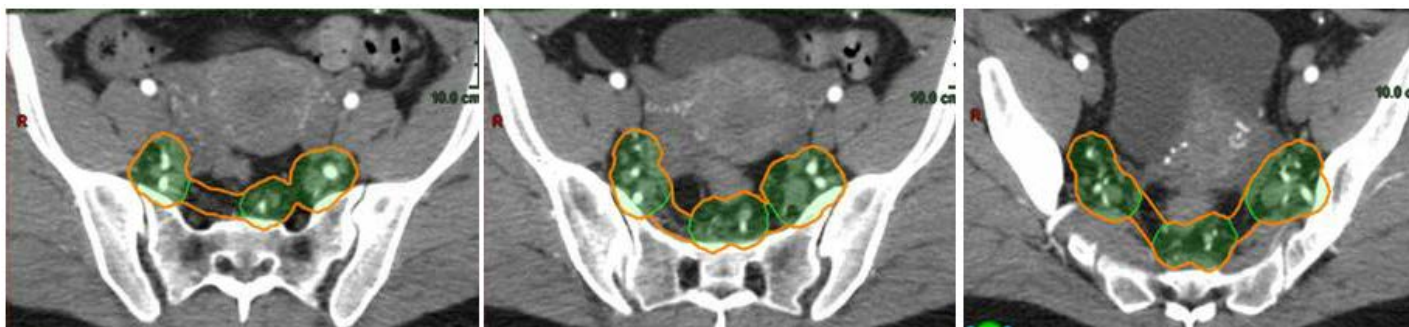
1. Identify the superior most level of ICTVE – this will be either at the junction of S1/S2 or 2 cm above GTV, whichever is most superior.
2. Starting at this level outline the internal iliac vessels (artery and vein combined), the inferior mesenteric artery and the superior rectal vessels. Tracing them inferiorly and posteriorly until reaching the level of the obturator internus muscle.



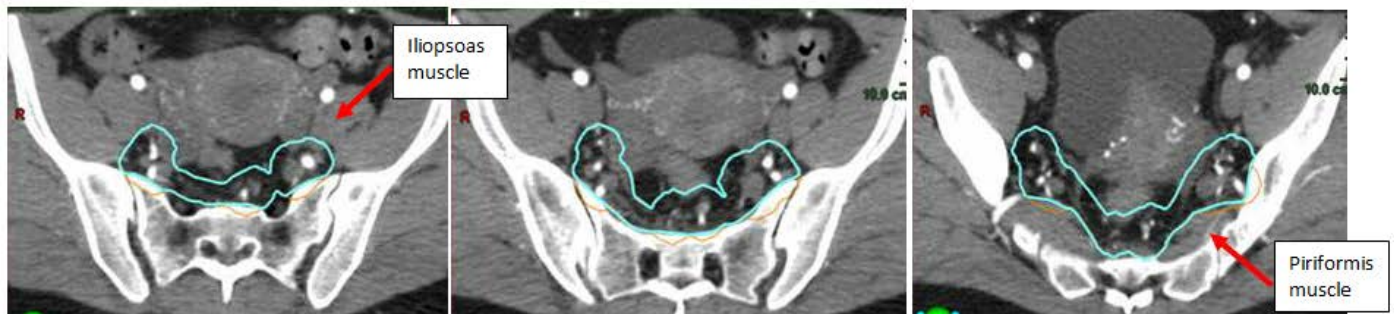
3. Add a 7 mm margin around the vessels, in all directions except in the superior-inferior direction.



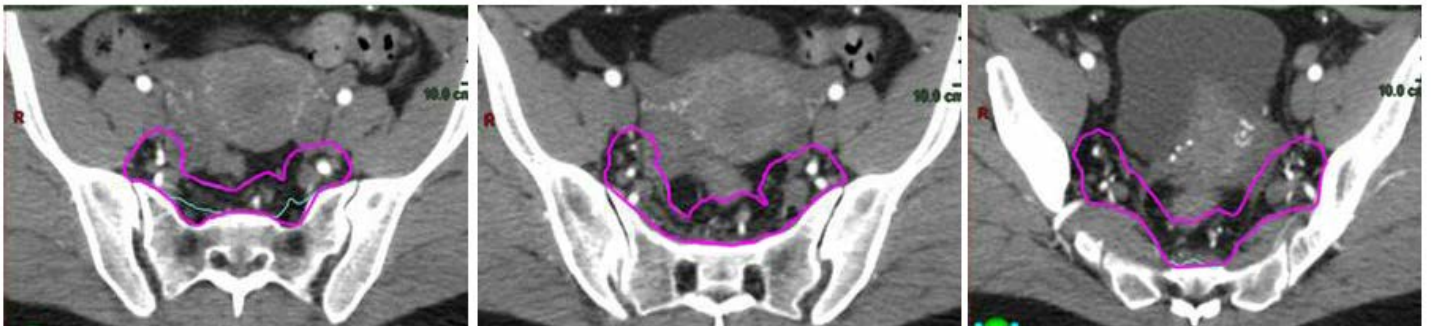
4. Using a 10 mm 'rollerball', join both volumes together along the anterior wall of the vertebra and sacrum to include the remaining pre-sacral nodes.



5. Manually edit the volume to exclude bone (unless there is infiltration into bone), piriformis muscles (posteriorly) and iliopsoas muscle (anterolaterally).

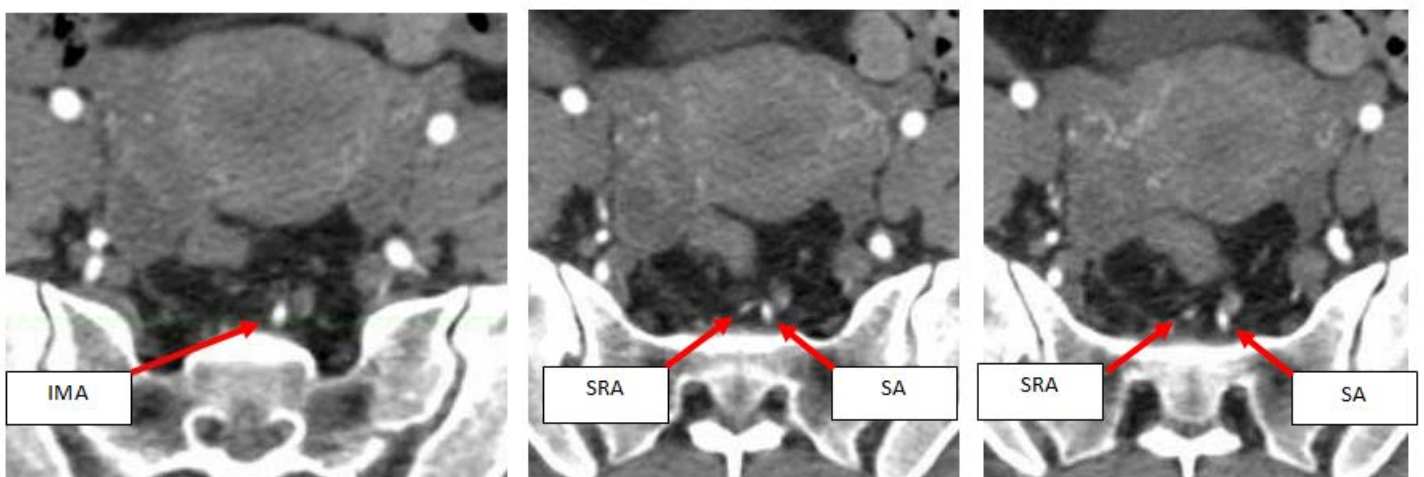


6. Manually edit volume to include sacral notch.

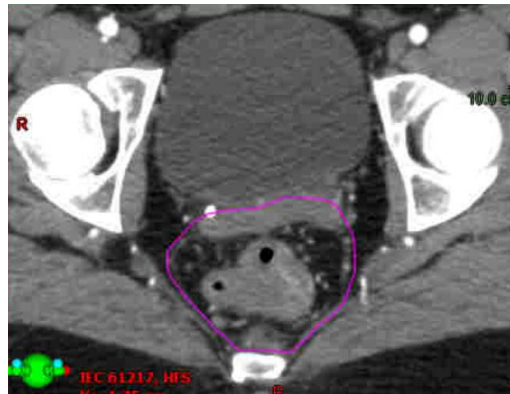


Mesorectum

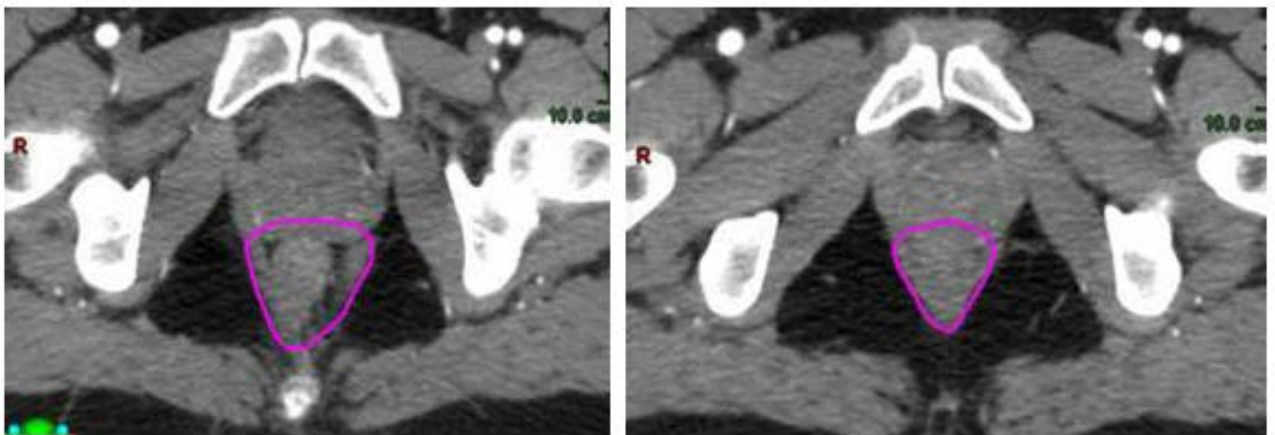
7. Identify the top of the mesorectum defined as either the bifurcation of the inferior mesenteric artery (IMA) into the sigmoid artery (SA) and superior rectal artery (SRA) OR if bifurcation of IMA to SA and SRA is difficult to identify, S2/3.



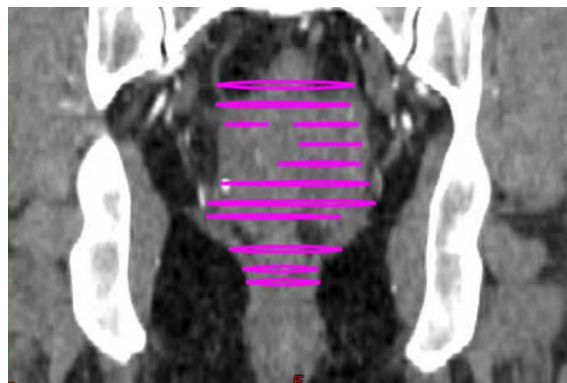
8. Delineate the whole mesorectum with an additional 1 cm anteriorly to allow for anterior motion. This will result in overlap of organs directly anterior to the mesorectum, for example, the uterus, prostate and so on.



9. The mesorectum continues inferiorly until insertion of the levator ani muscle into the external sphincter muscles (disappearing of the mesorectal fat around the rectum) or 2 cm below the inferior GTVp slice, therefore if appropriate continue the ICTV_Elec into the anal canal.. The levators should be included in the volume with the border being the outer wall of the levators .

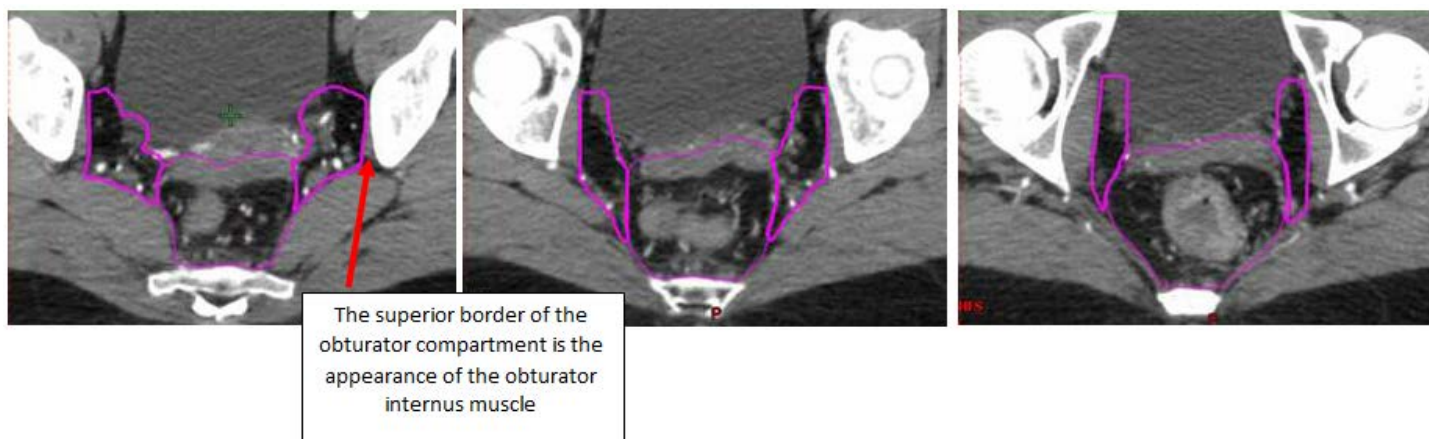


The inferior border can often be visualised more easily on coronal views.

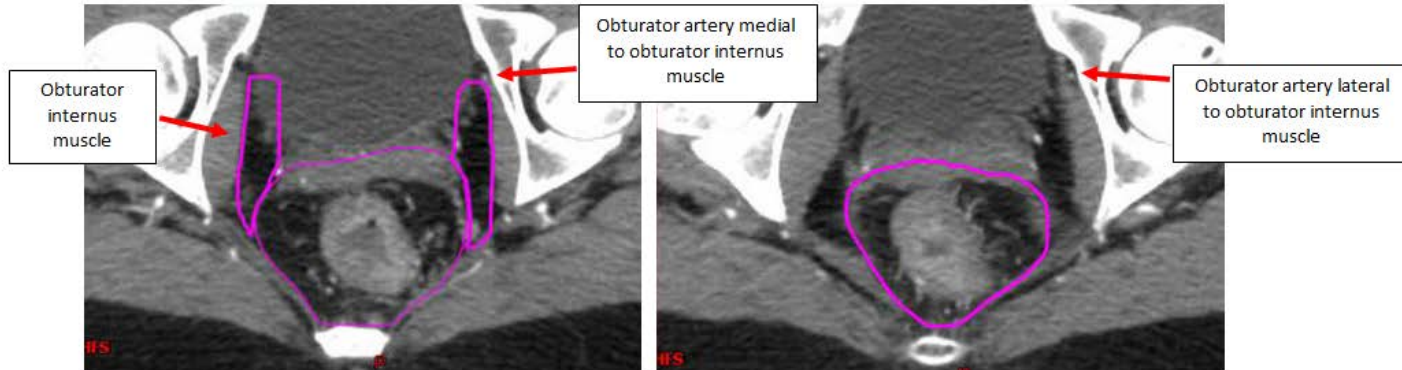


Obturator nodes

10. Identify the obturator internus muscle. Using a 17 mm 'rollerball' ensure the volume covers the medial aspect of this muscle until the obturator artery moves laterally to the muscle.



11. Where the obturator artery moves lateral to the obturator internus muscle, there are no more obturator nodes so the posterior border will take a large step from one slice to the other.



As detailed in the guidance:

- If neo-adjuvant chemotherapy has been used, the ICTV_Elec must cover all compartments that contained nodal disease at the outset. Where there was previously disease, superiorly the ICTV_Elec should be 2 cm above the most superior node at outset.
- Where there is radiological evidence suggestive of nodal involvement in any nodal compartment other than those outlined above (for example, external iliac node, ischiorectal fossa or inguinal node), this entire compartment should also be included. Guidance on delineation of these nodal groups can be found in the anal cancer guidance [www.analimrtguidance.co.uk].¹³

Appendix 5. Use of bowel cavity

The RTOG pelvic normal tissue consensus atlas suggests a bowel cavity for use with gynaecological and urological malignancies, favouring small bowel loops in GI malignancies.¹⁴ However, acknowledging centres may prefer the bowel cavity we provide contouring guidance and constraints should centres wish to use this OAR.

Organ	Standardised TPS name	Definition	Main reference
Bowel cavity	Spc_Bowel	Contour abdominal contents. Inferiorly from the most inferior small or large bowel loop (excluding rectum), whichever is most inferior. Contour to 2 cm superior to PTV. Exclude: CTV, muscles and major vasculature (common, internal and external iliac vessels) and subtract bladder and uterus (if relevant) from structure.	Gay 2012

Dose constraints for long-course chemoradiotherapy with bowel cavity

Organ at risk	OAR/target	Objective	Mandatory constraint
Bowel cavity [#]	D400cc	<20 Gy	
	D250cc	<30 Gy	
	D200cc	<43 Gy	<47.5 Gy
Femoral heads [*]	D50%	<30 Gy	<45 Gy
	D35%	<40 Gy	<50 Gy
	D5%	<50 Gy	<52.5 Gy
Bladder [*]	D50%	<35 Gy	<45 Gy
	D35%	<40 Gy	<50 Gy
	D5%	<50 Gy	<52.5 Gy
Genitalia [*]	D50%	<20 Gy	<35 Gy
	D35%	<30 Gy	<40 Gy
	D5%	<40 Gy	<52.5 Gy

[#]Constraints from in-house protocol in Leeds.

^{*}Constraints from anal cancer IMRT guidelines.¹³

Dose constraints for short-course radiotherapy with bowel cavity

Organ at risk	OAR/target	Objective
Bowel cavity [§]	D400cc	<10 Gy
	D250cc	<18 Gy
	D200cc	<23 Gy
Bladder [§]	D45%	<21 Gy

[§]Based on in-house protocol in Leeds.

Appendix 6. On-treatment CBCT image troubleshooting

Set-up

Images must be acquired using the same immobilisation and patient preparation as planning.

Match procedure

1. Treatment radiographers will undertake automated bony match using a ROI placed around PTV. Following this match, radiographers should perform a visual check of structures. A manual adjustment should be made if required to ensure a successful rigid registration. The success of the match must be checked on all planes.

Anatomy to be included (see Figure 4):

- Sacrum

Anatomy to be excluded:

- Pubic symphysis
- Femoral heads

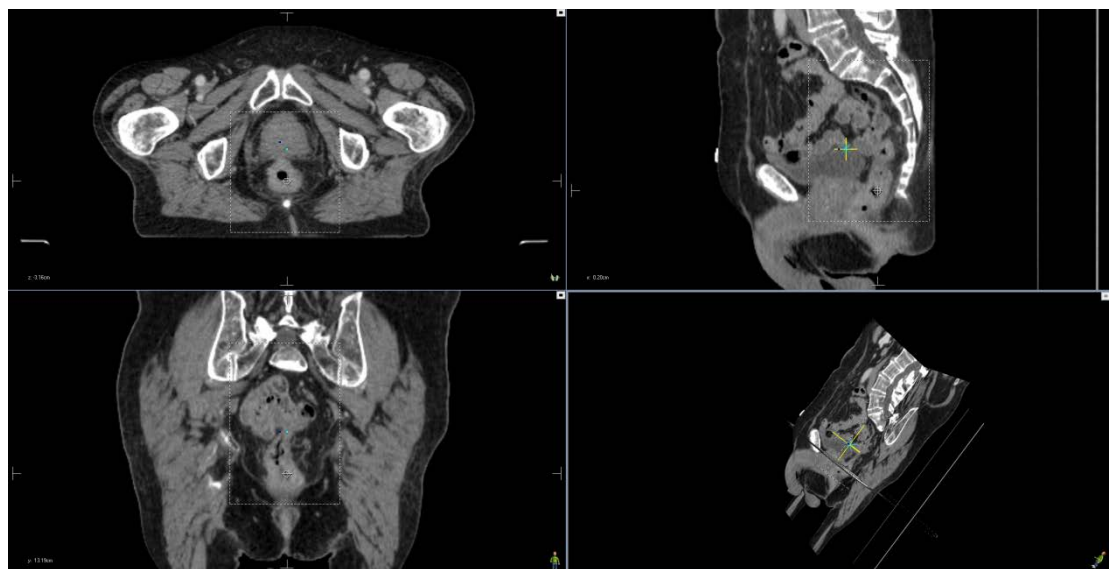


Figure 4: A planning CT image illustrating the use of a large automated matching clipbox which covers the sacrum.

2. Bladder/rectum volume/position should be checked. If gross change from planning is evident, follow troubleshooting advice later in this section.
3. The primary tumour, that is, GTVp may move independent of bone. It is essential to check primary tumour coverage following a bony match to ensure all targets are covered adequately by PTV. Note that primary tumour (GTVp), involved nodes (GTVn) and elective nodal volumes may all move independently. Bony matching can be used as a surrogate for most pelvic lateral and sacral nodes. Manual adjustments may be required and any adjustments should be checked on all planes (see Figures 5 and 6).
4. Where an SIB is planned and targets are visible on CBCT, coverage should be checked. Where involved nodes are included, both GTV targets should be localised, that is, GTVp and GTVn (if visible) to assess the effect of any differential motion (Figure 7).

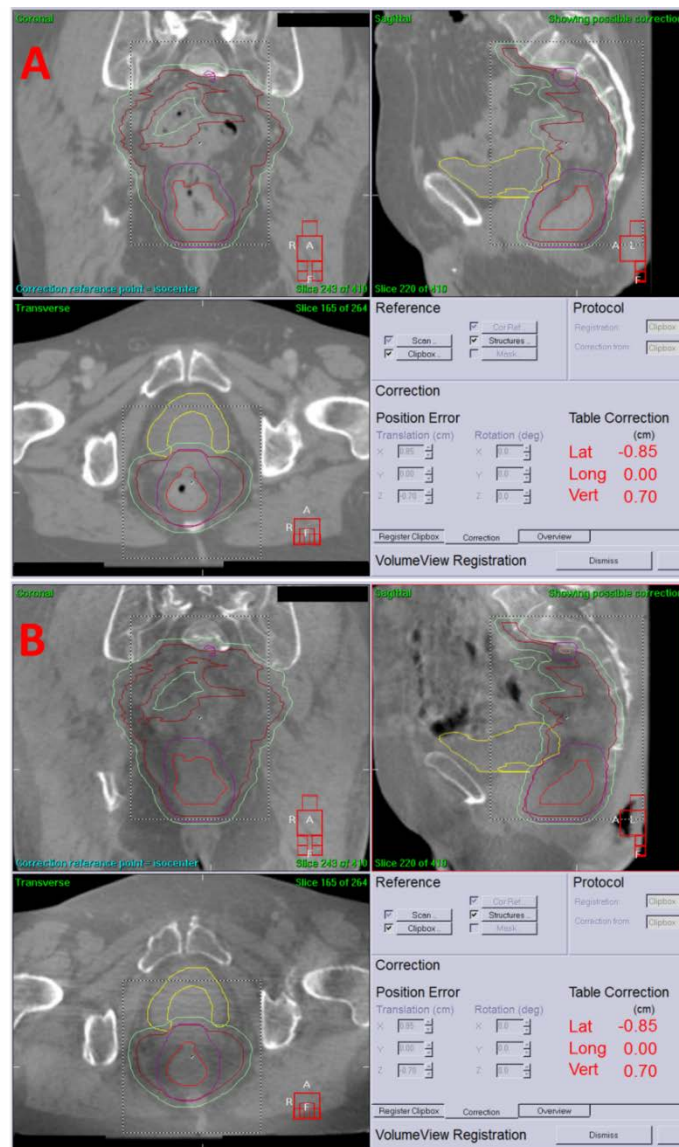


Figure 5a. Planning CT and **Figure 5b.** CBCT, demonstrating an example of a treatment plan with a superior nodal volume (GTVn) requiring consideration for potential differential motion.

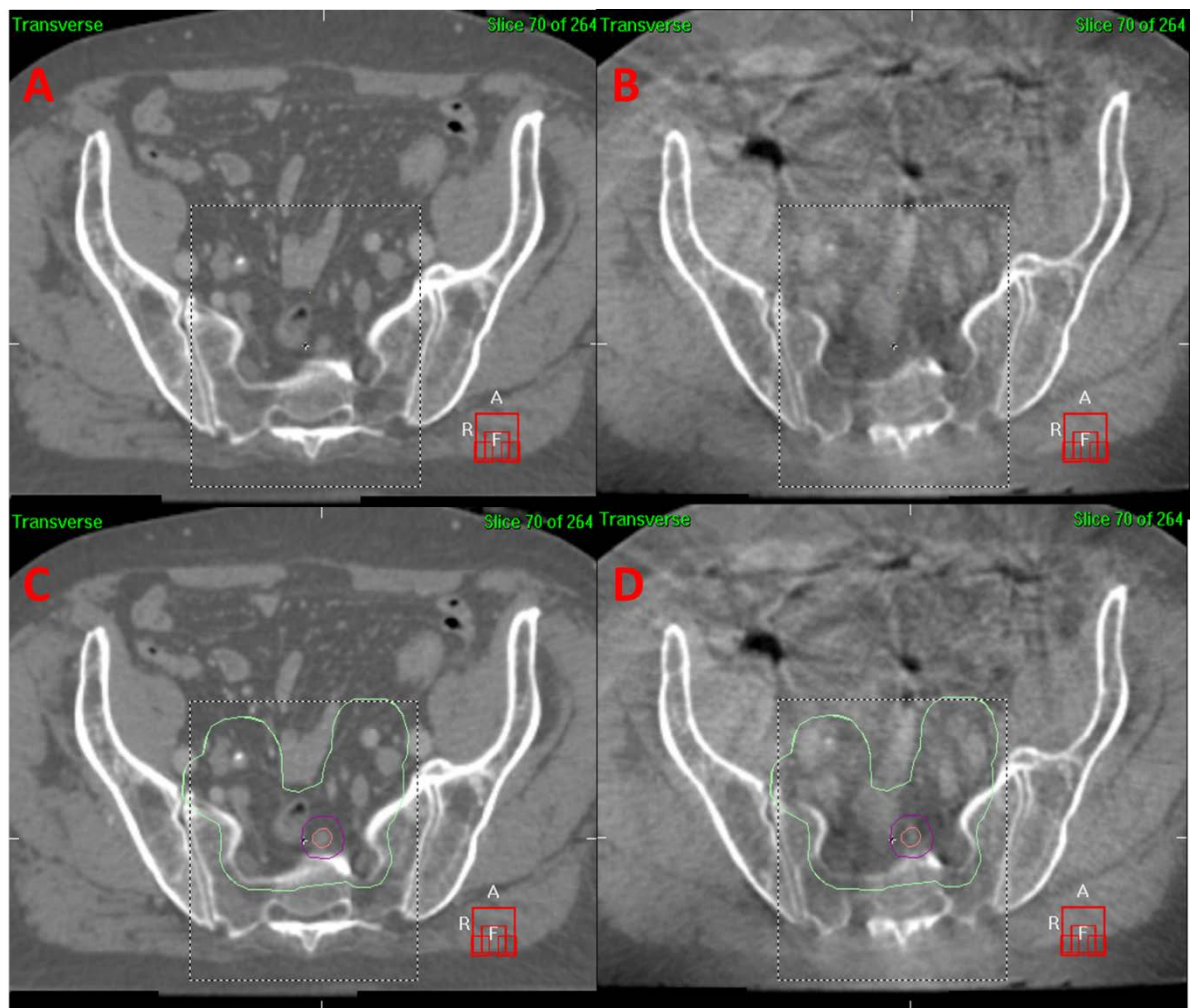


Figure 6: Axial images demonstrating the coverage of the superior node shown in Figure 5.

Figure 6a and **Figure 6b** show the planning CT and CBCT without structures and **Figure 6c** and **Figure 6d** show the planning CT and CBCT with the GTVn, PTV_High and PTV_Low structures. Careful use of windowing and selection or switching on/off of structures can be helpful especially with such small nodal targets. **Figures 5 and 6** demonstrate good coverage of the targets within the PTV_Low and the PTV_High.

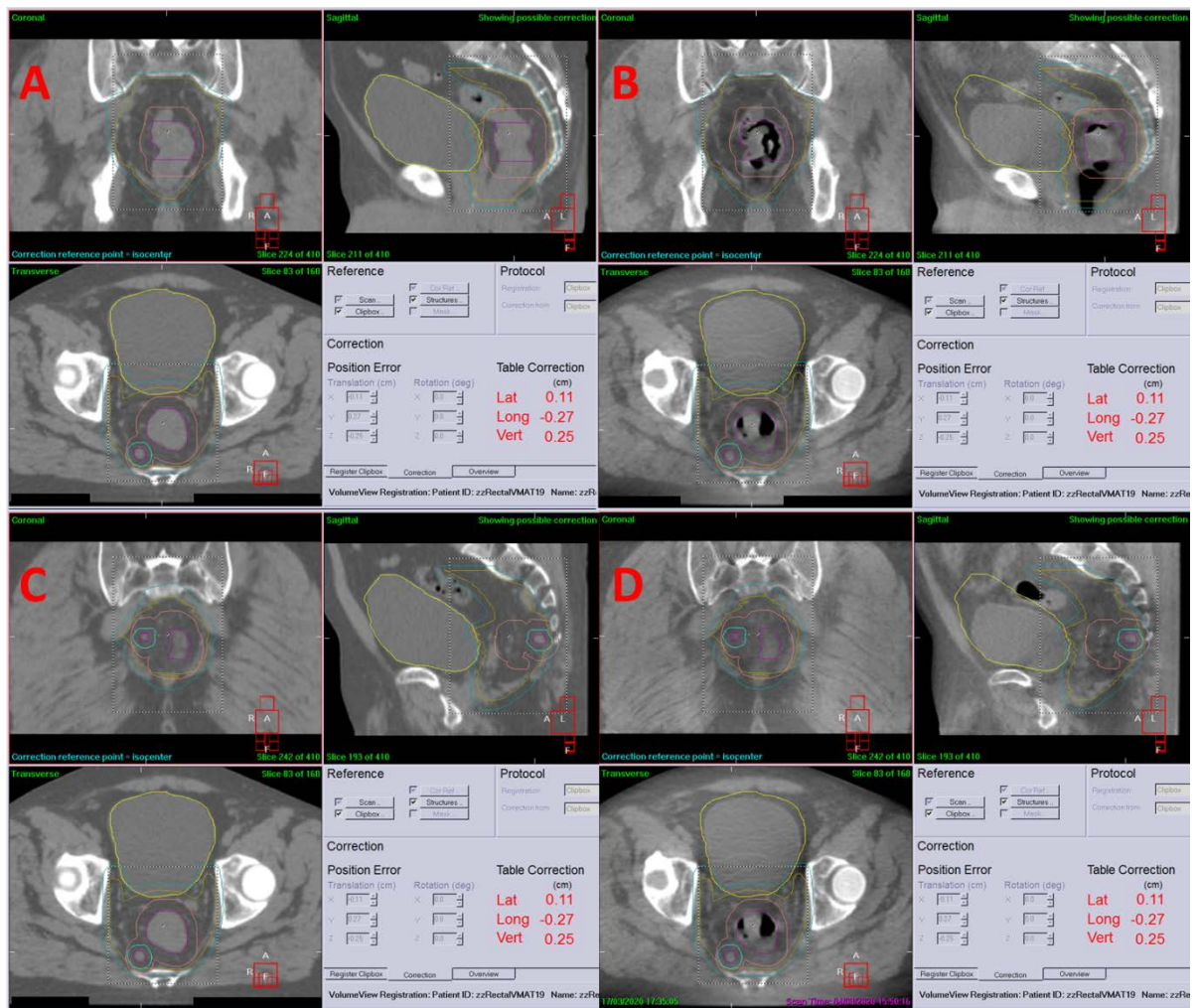


Figure 7. Example of treatment plan with SIB volume. **Figure 7a** and **Figure 7b** show the planning CT and CBCT at the level of the GTV; **Figure 7c** and **Figure 7d** show the planning CT and CBCT at the level of the nodal tumour volume. Despite the smaller bladder volume evident on the CBCTs compared to the CTs, the GTVp and GTVn (GTVn_Boost) are well covered by the PTV_High and PTV_Low.

Troubleshooting

If difficulty in matching occurs:

- Check the automatic pelvic match and manually adjust if necessary
- Check bony anatomy including pelvic rotation/tilt to identify any gross setup errors
 - Repeat set-up of patient as appropriate
 - kV imaging can be used to correct pelvic tilt
- Check for differences in bladder filling (especially if superior mesorectum not matching)
 - Patient to urinate/fill bladder accordingly (see Figure 8)
- Check for differences in rectal filling (acknowledging clinical background of patient) (see Figure 9 below)
 - Patient to be sent to open bowels

- Consider fleet/phosphate enema
 - If recurring issue, consider prescription for Movicol two sachets once daily
N.B. Suggested bladder and rectum filling is discussed in detail in [Appendix 1](#).
Suggested rectal filling protocol
- e. If all measures fail, the priority is to match the CTV at the level of the primary tumour and 2 cm above/below
- f. Where matching is problematic, staff should initiate MDT discussion to decide on corrective action.

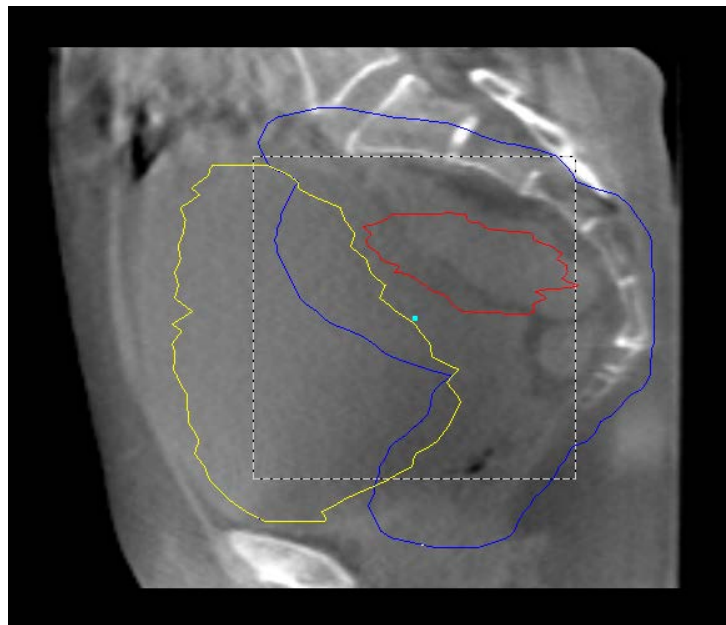


Figure 8: CBCT image demonstrating the potential impact of having a larger bladder than planned.

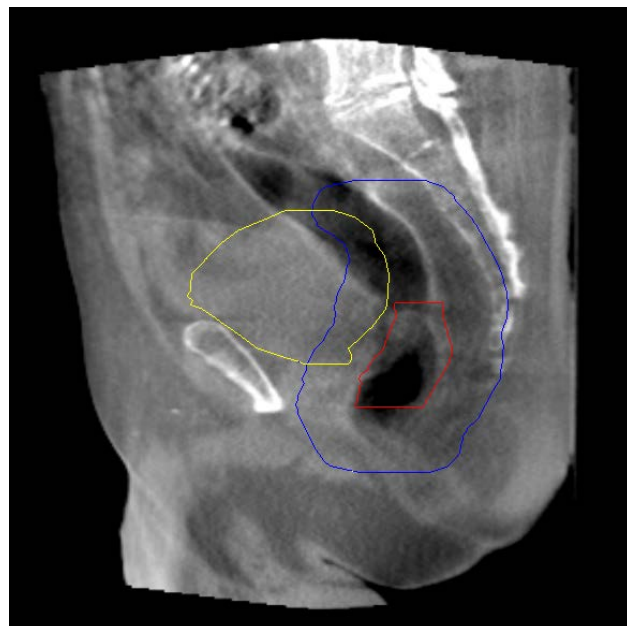


Figure 9. CBCT image demonstrating the potential impact of having a large rectal size due to gas.

Appendix 7. Contributors

Development team:

Richard Adams, Velindre
Ane Appelt, Leeds
Claire Arthur, The Christie
Matthew Beasley, Leeds
Aileen Duffton, Glasgow
Alexandra Gilbert, Leeds
Simon Gollins, North Wales
Catherine Hanna, Glasgow
Mark Harrison, Mount Vernon
Maria Hawkins, UCL
Kirsten Laws, Aberdeen
Rebecca Muirhead, Oxford – (Lead)
Sean O’Cathail, Glasgow
Patrizia Porcu, Royal Free
Maxwell Robinson, Oxford
David Sebag-Montefiore, Leeds
Finbar Slevin, Leeds
Mark Teo, Leeds
Suliana Teoh, Oxford

We would like to acknowledge the following for reviewing and informing guidance:

Ian Geh, Birmingham
Margaret King, Wolverhampton
Hamish Phillips, Edinburgh
Paul Hatfield, Leeds
Lucy Buckley, Christie
Tareq Abdulla, Glasgow
Alanna Morton, Glasgow
Rashmi Jadon, Cambridge
Nicholas Macleod, Glasgow
Les Samuel, Aberdeen

References

1. Kapiteijn E, Marijnen C, Nagtegaal I *et al.* Preoperative radiotherapy combined with total mesorectal excision for resectable rectal cancer. *N Eng J Med* 2001; **345**:638–646.
 2. David Sebag-Montefiore D, Stephens R, Steele R *et al.* Preoperative radiotherapy versus selective postoperative chemoradiotherapy in patients with rectal cancer (MRC CR07 and NCIC-CTG C016): a multicentre, randomised trial. *Lancet* 2009; **373**:811–820.
 3. van Gijn W, Marijnen CAM, Nagtegaal ID *et al.* Preoperative radiotherapy combined with total mesorectal excision for resectable rectal cancer: 12-year follow-up of the multicentre, randomised controlled TME trial. *Lancet Oncol* 2011; **12**(6): 575–582.
 4. Anna Martling A, Holm T, Johansson H *et al.* The Stockholm II trial on preoperative radiotherapy in rectal carcinoma. long-term follow-up of a population-based study. *Cancer* 2001; **92**:896–902.
 5. Bosset J-F, Collette L, Calais G *et al.* Chemotherapy with preoperative radiotherapy in rectal cancer. *N Eng J Med* 2006; **355**:1114–1123.
 6. Teoh S, Muirhead R. Rectal radiotherapy – intensity-modulated radiotherapy delivery, delineation and doses. *Clin Oncol (R Coll Radiol)* 2016; **28**(2): 93–102.
 7. Appelt AL, Ploen J, Vogelius IR, Bentzen SM, Jakobsen A. Radiation dose-response model for locally advanced rectal cancer after preoperative chemoradiation therapy. *Int J Radiat Oncol Biol Phys* 2013; **85**(1): 74–80.
 8. Chua YJ, Barbachano Y, Cunningham D *et al.* Neoadjuvant capecitabine and oxaliplatin before chemoradiotherapy and total mesorectal excision in MRI-defined poor-risk rectal cancer: a phase 2 trial. *Lancet Oncol* 2010; **11**(3): 241–248.
 9. Owens R, Mukherjee S, Padmanaban S *et al.* Intensity-modulated radiotherapy with a simultaneous integrated boost in rectal cancer. *Clin Oncol (R Coll Radiol)* 2019; **32**(1): 35–42.
 10. The Royal College of Radiologists. *Radiotherapy target volume definition and peer review*. London: The Royal College of Radiologists, 2017.
 11. Mayo CS, Moran JM, Bosch W *et al.* American Association of Physicists in Medicine Task Group 263: standardizing nomenclatures in radiation oncology. *Int J Radiat Oncol Biol Phys* 2018; **100**(4): 1057–1066.
 12. Hodapp N. The ICRU report 83: prescribing, recording and reporting photon-beam intensity-modulated radiation therapy (IMRT). *Strahlenther Onkol* 2012; **188**(1): 97–99.
 13. <http://analimrtguidance.co.uk/National-Guidance-IMRT-Anal-Cancer-V4-Jan17.pdf> (last accessed 7/1/2021)
 14. Gay HA, Barthold HJ, O'Meara E *et al.* Pelvic normal tissue contouring guidelines for radiation therapy: a Radiation Therapy Oncology Group consensus panel atlas. *Int J Radiat Oncol Biol Phys* 2012; **83**(3): e353–e362.
 15. Holyoake DLP, Partridge M, Hawkins MA. Systematic review and meta-analysis of small bowel dose-volume and acute toxicity in conventionally-fractionated rectal cancer radiotherapy. *Radiother Oncol* 2019; **138**: 38–44.
 16. Garofalo M, Moughan J, Hong T *et al.* RTOG 0822: A phase II study of preoperative (PREOP) chemoradiotherapy (CRT) utilizing IMRT in combination with capecitabine (C) and oxaliplatin (O) for patients with locally advanced rectal cancer. *Int J Radiat Oncol Biol Phys* 2011; **81**(2): s3–s4.
 17. Radiotherapy Board. *On target 2: updated guidance for image-guided radiotherapy*. London: Radiotherapy Board, 2021 (in press at time of publications).
 18. ARISTOTLE: a phase III trial comparing standard versus novel chemoradiation treatment (CRT) as pre-operative treatment for magnetic resonance imaging (MRI)-defined locally advanced rectal cancer. ISRCTN09351447 <https://doi.org/10.1186/ISRCTN09351447>.
-





The Royal College of Radiologists
63 Lincoln's Inn Fields
London WC2A 3JW

+44 (0)20 7405 1282
enquiries@rcr.ac.uk
www.rcr.ac.uk
@RCRadiologists

The Royal College of Radiologists is a Charity
registered with the Charity Commission No.
211540

The Royal College of Radiologists. *National rectal cancer intensity-modulated radiotherapy (IMRT) guidance*. London: The Royal College of Radiologists, 2021.
Ref No. BFCO(21)1

© The Royal College of Radiologists, January 2021.

For permission to reproduce any of the content contained
herein, please email: permissions@rcr.ac.uk

This material has been produced by The Royal College of Radiologists (RCR) for use internally within the specialties of clinical oncology and clinical radiology in the United Kingdom. It is provided for use by appropriately qualified professionals, and the making of any decision regarding the applicability and suitability of the material in any particular circumstance is subject to the user's professional judgement.

While every reasonable care has been taken to ensure the accuracy of the material, RCR cannot accept any responsibility for any action taken, or not taken, on the basis of it. As publisher, RCR shall not be liable to any person for any loss or damage, which may arise from the use of any of the material. The RCR does not exclude or limit liability for death or personal injury to the extent only that the same arises as a result of the negligence of RCR, its employees, Officers, members and Fellows, or any other person contributing to the formulation of the material.