



## ORIGINAL ARTICLE

# Evaluation of the implementation of the sigmoid take-off landmark in the Netherlands

Sanne-Marije J. A. Hazen<sup>1</sup> | Tania C. Sluckin<sup>1</sup> | Karin Horsthuis<sup>2</sup> |  
Doenja M. J. Lambregts<sup>3</sup> | Regina G. H. Beets-Tan<sup>3,4</sup> | Pieter J. Tanis<sup>5</sup> |  
Miranda Kusters<sup>1</sup> | the Dutch Snapshot Research Group†

<sup>1</sup>Department of Surgery, Cancer Center Amsterdam, Amsterdam University Medical Centers, Vrije Universiteit Amsterdam, Amsterdam, The Netherlands

<sup>2</sup>Department of Radiology, Cancer Center Amsterdam, Amsterdam University Medical Centers, Vrije Universiteit Amsterdam, Amsterdam, The Netherlands

<sup>3</sup>Department of Radiology, The Netherlands Cancer Institute, Amsterdam, The Netherlands

<sup>4</sup>GROW School of Oncology and Developmental Biology, University of Maastricht, Maastricht, The Netherlands

<sup>5</sup>Department of Surgery, Cancer Center Amsterdam, Amsterdam University Medical Centers, University of Amsterdam, Amsterdam, The Netherlands

## Correspondence

Miranda Kusters, Department of Surgery, Amsterdam University Medical Centers, Vrije Universiteit Amsterdam, De Boelelaan 1117, PO Box 7057, 1007 MB, Amsterdam, The Netherlands.  
Email: m.kusters@amsterdamumc.nl

## Abstract

**Aim:** The sigmoid take-off (STO), the point on imaging where the sigmoid sweeps ventral from the sacrum, was chosen as the definition of the rectum during an international Delphi consensus meeting and has been incorporated into the Dutch guidelines since October 2019. The aim of this study was to evaluate the implementation of this landmark 1 year after the guideline implementation and to perform a quality assessment of the STO training.

**Method:** Dutch radiologists, surgeons, surgical residents, interns, PhD students and physician assistants were asked to complete a survey and classify 20 tumours on MRI as 'below', 'on' or 'above' the STO. Outcomes were agreement with the expert reference, inter-rater variability and accuracy before and after the training.

**Results:** Eighty-six collaborators participated. Six radiologists (32%) and 11 surgeons (73%) used the STO as the standard landmark to distinguish between rectal and sigmoidal tumours during multidisciplinary meetings. Overall agreement with the expert reference improved from 53% to 70% ( $p < 0.001$ ) after the training. The positive predictive value for diagnosing rectal tumours was high before and after the training (92% vs. 90%); the negative predictive value for diagnosing sigmoidal tumours improved from 39% to 63%.

**Conclusion:** Approximately half of the represented hospitals have implemented the new definition of rectal cancer 1 year after the implementation of the Dutch national guidelines. Overall baseline agreement with the expert reference and accuracy for the tumours around the STO was low, but improved significantly after training. These results highlight the added value of training in implementation of radiological landmarks to ensure unambiguous assessment.

## KEYWORDS

implementation, magnetic resonance imaging, rectal cancer, sigmoid cancer, sigmoid take-off

†Participating members of the Dutch Snapshot Research Group appear in Appendix C.

## INTRODUCTION

Distinguishing the rectum from the sigmoid colon is important, as cancer treatment strategies differ for these two locations. Various definitions of the rectum have previously been used, such as 15 cm from the anal margin, the peritoneal reflection or the line between the pubic bone and promontory [1]. This may have resulted in over- or under-treatment and could have caused bias in previous scientific research [2–5]. Locally advanced rectal tumours require neoadjuvant (chemo)radiotherapy ((C)RT) to increase the possibility of a complete resection and have a different surgical approach from sigmoidal tumours [3]. On the contrary, colon tumours are seldom treated with neoadjuvant (C)RT and adjuvant chemotherapy has a clear survival benefit depending on nodal status, while its role in rectal cancer is still controversial [6,7]. Both the most recent European Society for Medical Oncology guidelines and the American Society of Colon and Rectal Surgeons recommend that rectal cancer be classified as a tumour located within 15 cm of the anal verge; the Japanese, ACPGBI and the previous Dutch guidelines do not mention a definition at all [8–11]. International consensus was recently obtained amongst multi-disciplinary colorectal experts, and the sigmoid take-off (STO), the point on imaging where the sigmoid sweeps ventral and horizontal from the sacrum, was chosen as the preferred anatomical landmark between the sigmoid colon and the rectum based on radiological imaging [12].

The landmark was implemented in the updated Dutch national guidelines, published online in October 2019 [13]. The guidelines define a rectal tumour where the lower border is located distal to the STO. All members of the Dutch Association of Coloproctology were informed of the Delphi consensus article through a newsletter in October 2019 and the new definition was further explained during regional meetings [12]. In the newsletter of December 2020, the definition was announced to be included in the annual national registration of rectal resections in Dutch hospitals and this was the official moment that Dutch hospitals were obliged to use the new definition of rectal cancer for the national registration audit.

In the current national snapshot audit on rectal cancer, the new definition of a rectal tumour will be checked by the local collaborators on the MR images of all included patients. This is a national cross-sectional retrospective study, including patients who were registered as having a rectal tumour according to the local definition and underwent resection in 2016, to evaluate the diagnostics and treatment of rectal cancer. To achieve uniform assessment of the STO an online training module was created prior to the data collection. Participants were asked to assess multiple MRIs before and after the training. The aim of the current study was to evaluate the current implementation of the STO landmark and to perform a quality control assessment of the 'sigmoid take-off training' up to the official inclusion of the definition in the annual national registration.

### What does this paper add to the literature?

Defining a tumour as rectal or sigmoidal has important clinical implications. Evaluating the implementation of the new radiological landmark, the sigmoid take-off, is therefore necessary. The results of this study highlight the added value of training to ensure unambiguous assessment.

## METHOD

### Definition of the STO

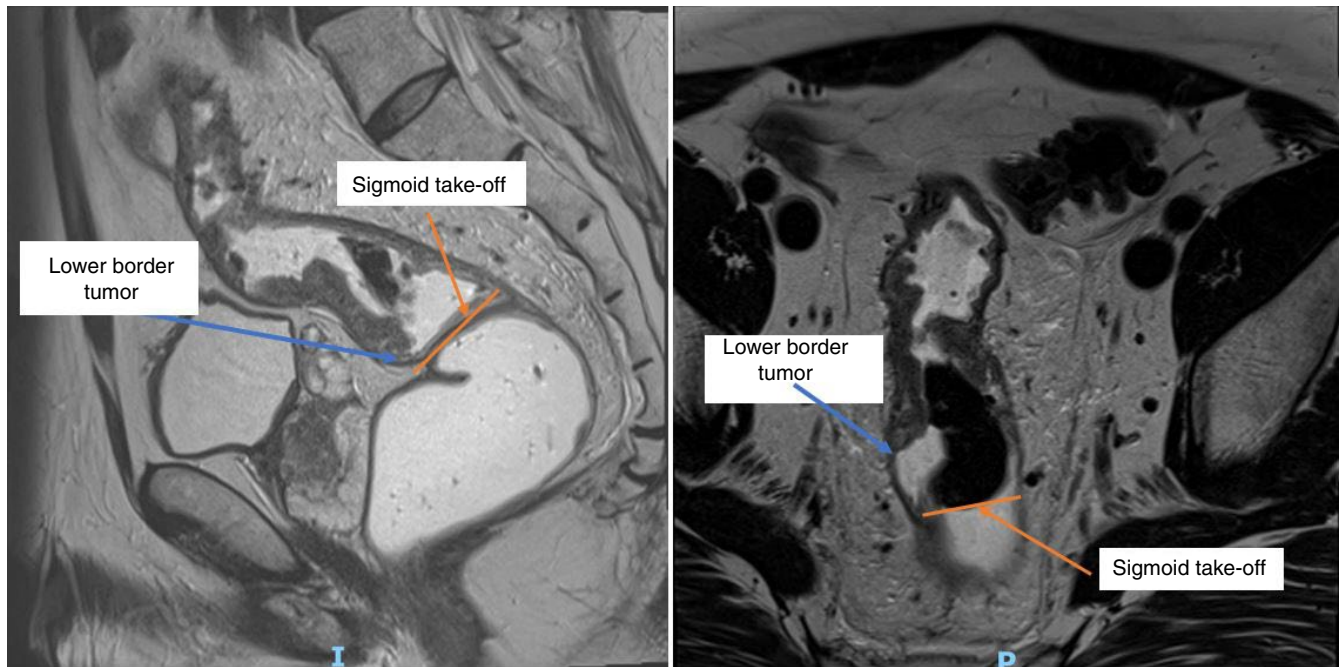
The STO can be identified on the sagittal and axial view on MRI or CT. The STO is the point where the fixated mesorectum ends and the mobile mesocolon begins. This is visible on imaging as the point where the sigmoid colon makes a horizontal sweep on the sagittal view and a ventral sweep on the axial view and thus forms the border between the sigmoid and rectum. The Dutch guidelines have incorporated this landmark further in the definition of a rectal tumour. A rectal tumour is defined as a tumour with its lower border situated on or below the level of the STO, while a sigmoid tumour is defined as a tumour with its lower border situated above the level of the STO. Figure 1 shows an example MRI with a sagittal and axial view where the STO is marked.

### Participants

All collaborators in the snapshot rectal cancer 2016 study, approximately 200 physicians, were invited by e-mail to participate in the online training; answers until 23 December 2020 were included in this analysis. A snapshot study has a collaborative cross-sectional study design, allowing a large amount of population-based data to be collected in a short time frame [14]. In every participating centre, a local collaborators team, consisting of a surgeon together with one or two surgical residents, interns, PhD students (involved in rectal cancer research) or physician assistants (PAs) with an interest in colorectal surgery, and a radiologist were responsible for the data collection.

### Training

The training consisted of three sections: baseline assessment of multiple MRIs, a training document (Appendix B) and a quality assessment, which were shared in a PowerPoint format. This training was created by the steering committee of the Snapshot rectal cancer 2016 study, with members who were also present at the Delphi consensus meeting and are part of the Dutch colorectal cancer guidelines committee.



**FIGURE 1** Sagittal (left) and axial view (right) of the sigmoid take-off. The lower border of the tumour (blue arrow) and the sigmoid take-off landmark (orange arrow) are indicated. This tumour is located with its lower border above the sigmoid take-off and should therefore be classified as a sigmoid tumour

To determine the baseline assessments, participants received 20 anonymized cases with both sagittal and axial image planes of the baseline MRI scan, in which both the tumour and the STO were visible. No further information regarding the STO was provided beforehand. Participants were asked to classify the tumour as above, on or below the STO. Additional questions were asked about their current knowledge and use of the STO. Furthermore, the surgical residents, interns, PhD students and PAs were also asked to score their ability to assess a MR image on a scale from 1–10.

After completing the baseline survey, a training document with background information regarding the STO was sent, with tips on how to identify this point and how to measure the tumour in relation to the STO. Five different cases with a sagittal and axial view of the STO, marked as indicated by the expert reference, were shown (Appendix B). A more extensive version of this document was made available for surgical residents, interns, PhD students and PAs, with additional information explaining the basics of MRI.

After the training, participants were asked to analyse the same 20 anonymized cases again, but in random order, without knowing their scores from the first attempt. The surgeons and radiologists were asked if they would use the STO landmark in the future during multidisciplinary team (MDT) meetings.

### Patient cases

Twenty cases were selected for the online assessment. These cases were preselected with representative imaging to be allow assessment

of the anatomy of the STO. Various distal rectal tumours, mid-rectal tumours and sigmoidal tumours were included. These patients were initially all diagnosed as having a rectal tumour before the new definition was introduced.

### Types of classifications

Nine cases had a clear rectal location ('evident cases') and 11 cases had a tumour around the STO ('nonevident cases') (Appendix A). The position of the tumour was classified into three groups: lower border of the tumour situated 'above' ( $n = 3$ ), 'on' ( $n = 3$ ) or 'below' ( $n = 14$ ) the STO. Expert reference answers were obtained during a consensus meeting.

### Statistics

The data were processed using IBM SPSS Statistics (version 26.0). Categorical variables are described using  $n$  and percentages, continuous variables are denoted using mean and standard deviation (SD) or median with the range. The primary outcome was the agreement with the expert reference in locating the tumour above, on or below the STO. The generalized estimating equation was used to compare the scores in percentages before and after the training. Because of multiple testing, a  $p$ -value of  $<0.01$  was considered statistically significant.

The interrater reliability (IRR) was calculated by the intraclass correlation coefficient (ICC). The IRR was defined as poor for ICC

values less than 0.40, fair for 0.40–0.59, good for 0.60–0.74 and excellent for 0.75–1.0 [15]. The ICC was noted as single and average measures due to the large number of participants. The accuracy of subsequently defining the tumour as rectal or sigmoidal was analysed by the sensitivity, specificity, positive predictive value (PPV) and negative predictive value (NPV) using the expert scores as a reference. To determine accuracy, the outcomes were converted into binary variables: 'on' and 'under' were classified as 'rectal tumour' (positive) and 'above' was classified as 'sigmoidal tumour' (negative), according to current Dutch guidelines and common use in daily practice.

## RESULTS

### Responders

A total of 86 collaborators participated from seven academic hospitals, 30 teaching hospitals and eight nonteaching hospitals. All surgeons ( $n = 15$ ) were specialists in colorectal surgery with a median experience of 10 years [interquartile range (IQR) 7–20 years]. All radiologists ( $n = 19$ ) were specialist abdominal radiologists with a mean experience of 8 years (IQR 4–18 years). Baseline characteristics are shown in Table 1.

### MRI assessment

Surgeons rated their own ability in assessing a rectal MRI scan with a median of 7.5 (range 6.0–9.0) on a scale of 1–10. The residents, interns, PhD students and PAs initially scored themselves as insufficient, but this improved after training: residents scored 5.0 (range 2.0–7.0) before and 6.0 (range 5.0–9.0) after training ( $p < 0.001$ ), interns scored 3.0 (range 1.0–7.0) before and 6.0 (range 4.0–8.0) after training ( $p < 0.001$ ), PhD students improved from 6.0 (range 2.0–6.0) to 7.0 (range 5.0–8.0) ( $p = 0.035$ ) and PAs scored 4.0 (range 1.0–5.0) before and 6.0 (range 5.0–7.5) after training ( $p = 0.003$ ).

### Use of the consensus definition

A total of 95% of the radiologists and 93% of the surgeons were already familiar with the STO definition. Fifty five per cent ( $n = 47$ ) of all study participants used the STO as their standard definition of the rectum. Other definitions used were: below the peritoneal reflection ( $n = 20$ ; 24%) and  $\leq 15$  cm from the anus ( $n = 7$ ; 8%), the line between promontory and pubic bone,  $\leq 10$  cm from the anus, below the curve of S2/S3 and the disappearances of anatomical characteristics of the colon (omental appendices, haustra and the taeniae coli; however, those are intraoperative findings and are not able to be determined on preoperative imaging).

**TABLE 1** Baseline characteristics

	Radiologists	Colorectal surgeons	Surgical residents	Surgical interns	PhD students	Physician assistants
No. of participants	19	15	20	22	5	5
Type of hospital						
University	2 (10.5%)	3 (20.0%)	4 (20.0%)	1 (4.5%)	3 (60.0%)	0
Teaching	14 (73.7%)	9 (60.0%)	16 (80.0%)	20 (90.9%)	2 (40.0%)	3 (60.0%)
Nonteaching	3 (15.8%)	3 (20.0%)	0	1 (4.5%)	0	2 (40.0%)
Median years of experience (IQR) <sup>a</sup>	8 (4–18)	10 (7–20)	4 (2–5)	1.3 (1–2.6)	1 (0.2–missing)	6.5 (1.5–13.5)
Other experience						
PhD rectal cancer	1 (5.3%)	1 (6.7%)	7 (36.8%)	2 (9.1%)	0	0
Scientific research	2 (10.5%)	6 (40%)	2 (10.5%)	6 (27.3%)	5 (100%)	1 (20.0%)
Familiar with sigmoid take-off definition						
Yes	18 (94.7%)	14 (93.3%)	16 (80.0%)	10 (45.5%)	3 (60.0%)	4 (80.0%)
No	1 (5.3%)	1 (6.7%)	4 (20.0%)	12 (54.5%)	2 (40.0%)	1 (20.0%)
Own definition of rectum <sup>b</sup>						
Sigmoid take-off	13 (68.4%)	11 (68.8%)	10 (55.6%)	9 (45.0%)	2 (40.0%)	3 (60.0%)
Below the peritoneal reflection	4 (21.1%)	2 (13.3%)	4 (22.2%)	7 (35.0%)	1 (20.0%)	2 (40.0%)
$\geq 15$ cm from the anus	2 (10.5%)	1 (6.3%)	0	3 (15.0%)	1 (20.0%)	0
Promontory - pubic bone	0	0	1 (5.6%)	0	0	0
Other	0	1 (6.3%)	3 (16.8%)	2 (10.0%)	1 (20%)	0

Abbreviation: IQR, interquartile range.

<sup>a</sup>The years of experience was missing in three surgical interns, two surgical PhD students and one surgical physician assistant.

<sup>b</sup>Own definition of the rectum was missing in one surgical resident and two surgical interns.

## The sigmoid take-off in MDTs

Six radiologists (32%) used the STO as the standard landmark during MDT meetings, 11 (58%) said its use varied in frequency and two radiologists (11%) did not use this definition. The radiologists were present at 35% (mean) of the colorectal MDT meetings in their hospital. In contrast, 11 surgeons (73%) routinely used the STO, with only three (20%) answering that this varied in frequency; one (7%) said it was not used. The difference in use of the STO did not differ significantly between the surgeons and radiologists ( $p = 0.05$ ). When the STO was used as the standard landmark, this was implemented after a median of 2 months (IQR 1–5 months) since the publication of the new guidelines. After the training, all surgeons and radiologists answered they were planning to use the STO as the standard landmark or that they were already using it.

## Agreement with expert reference and interrater reliability

Agreement with the expert reference (i.e. overall accuracy) before and after the training, is shown in Table 2, separately for all groups. The agreement rates for all cases before and after the training showed significantly higher rates for all groups, except for the surgeons. The total agreement increased from 53% to 70% after the training ( $p < 0.001$ ). When analysing the specialized participants (radiologists and surgeons) and nonspecialized participants (surgical residents, interns, PhD students and PAs) separately, the specialized participants improved from 58% to 73% ( $p < 0.001$ ) and the nonspecialized participants improved from 50% to 69% ( $p < 0.001$ ). The agreement rates for the evident cases did not differ significantly before and after the training. The agreement rate for nonevident cases increased significantly for all groups, except for the surgeons and PAs. There was no significance in the rates before and after the training when comparing surgeons and radiologists who already used the STO as the standard landmark in MDTs compared with those who did not ( $p = 0.765$  and  $p = 0.625$ ).

The scores per case are shown in Table 3. The agreement with the expert reference improved for 16 of the 20 cases, but decreased for cases 7, 8, 10 and 15 after the training.

The ICC is shown in Table 4. The single-measures ICC indicated fair IRR before and after the training for the total group and poor IRR for the evident and not evident groups. The average-measures ICC showed excellent IRR for all groups before and after the training.

## Diagnostics

The overall sensitivity to diagnose rectal cancer as the positive outcome (versus sigmoid cancer as the negative outcome) was 85% for all cases before the training and improved to 96% after the training. The specificity was 55% before and 38% after the training. PPV was 92% and became 90% after the training. The

TABLE 2 Agreement with expert reference before and after training for the evident cases, nonevident cases and all cases

	Evident cases			Nonevident cases			All cases		
	Before	After	p-value	Before	After	p-value	Before	After	p-value
Radiologists	85% (n = 146/171)	94% (n = 160/171)	- <sup>a</sup>	31% (n = 65/209)	61% (n = 127/209)	<0.001	56% (n = 211/380)	76% (n = 287/380)	<0.001
Surgeons	80% (n = 108/135)	87% (n = 117/135)	0.629	42% (n = 69/165)	50% (n = 83/165)	0.036	59% (n = 177/300)	67% (n = 200/300)	0.018
Surgical residents	69% (n = 125/180)	89% (n = 161/180)	0.240	36% (n = 80/220)	50% (n = 110/120)	0.004	51% (n = 205/400)	68% (n = 271/400)	<0.001
Surgical interns	57% (n = 113/198)	90% (n = 178/198)	0.092	36% (n = 87/242)	49% (n = 119/242)	0.001	46% (n = 200/440)	68% (n = 297/440)	<0.001
PhD students	76% (n = 34/45)	96% (n = 43/45)	0.550	40% (n = 22/55)	56% (n = 31/55)	0.001 <sup>b</sup>	56% (n = 56/100)	74% (n = 74/100)	<0.001
Physician assistants	71% (n = 32/45)	89% (n = 40/45)	0.617	40% (n = 22/55)	56% (n = 31/55)	0.124 <sup>b</sup>	54% (n = 54/100)	71% (n = 71/100)	<0.001
Total	72% (n = 558/774)	90% (n = 697/774)	0.038	37% (n = 345/946)	53% (n = 501/946)	<0.001	53% (n = 903/1720)	70% (1198/1720)	<0.001

<sup>a</sup>The p-value could not be computed because the estimated mean parameter of the distribution is outside its range.

<sup>b</sup>The difference in p-value is most likely caused by the difference in distribution of the individuals scores within the groups.

**TABLE 3** Agreement with expert reference per case before and after the training

Case	Reference	Baseline				After training			
		Under	On	Above	Score	Under	On	Above	Score
1	Under	92%	6%	2%	92%	98%	0%	2%	98%
2	Under	30%	31%	38%	30%	63%	24%	13%	63%
3	Under	93%	6%	1%	93%	99%	0%	1%	99%
4	Under	2%	59%	17%	2%	67%	24%	7%	67%
5	Under	11%	74%	15%	11%	65%	35%	0%	65%
6	Under	99%	1%	0%	99%	100%	0%	0%	100%
7	On	19%	59%	22%	59%	55%	37%	8%	37%
8	On	28%	47%	26%	47%	42%	44%	14%	44%
9	Under	33%	47%	21%	33%	79%	20%	1%	79%
10	Above	11%	50%	40%	40%	27%	67%	6%	6%
11	Under	73%	20%	7%	73%	94%	4%	2%	94%
12	Under	45%	54%	1%	45%	94%	6%	0%	94%
13	Under	14%	66%	20%	14%	56%	41%	4%	56%
14	Under	73%	19%	8%	73%	70%	22%	8%	70%
15	Above	14%	26%	61%	61%	22%	36%	42%	42%
16	Under	65%	35%	0%	65%	95%	5%	0%	95%
17	Under	78%	21%	1%	78%	98%	2%	0%	98%
18	Under	6%	59%	35%	6%	41%	57%	2%	41%
19	Above	7%	27%	66%	66%	9%	24%	66%	66%
20	On	5%	43%	52%	43%	15%	79%	6%	79%

**TABLE 4** Intraclass correlation coefficient (ICC) before and after the training for all cases and separately for the evident cases and nonevident cases and the specialized participants (radiologists and surgeons) and the nonspecialized participants (surgical residents, interns, PhD students and physician assistants)

	Baseline		After training	
	Single measures	Average measures	Single measures	Average measures
All cases	0.427 (95% CI 0.298–0.617)	0.985 (95% CI 0.973–0.993)	0.424 (95% CI 0.295–0.972)	0.984 (95% CI 0.972–0.993)
Specialized participants	0.414 (95% CI 0.280–0.608)	0.960 (95% CI 0.930–0.981)	0.473 (95% CI 0.334–0.62)	0.968 (95% CI 0.945–0.985)
Nonspecialized participants	0.474 (95% CI 0.338–0.661)	0.979 (95% CI 0.964–0.990)	0.409 (95% CI 0.281–0.601)	0.973 (95% CI 0.953–0.987)
Evident cases	0.271 (95% CI 0.140–0.583)	0.969 (95% CI 0.932–0.992)	0.165 (95% CI 0.077–0.432)	0.943 (95% CI 0.875–0.985)
Specialized participants	0.139 (95% CI 0.056–0.399)	0.846 (95% CI 0.668–0.958)	0.110 (95% CI 0.039–0.347)	0.808 (95% CI 0.579–0.948)
Nonspecialized participants	0.374 (95% CI 0.206–0.692)	0.969 (95% CI 0.931–0.992)	0.190 (95% CI 0.087–0.477)	0.924 (95% CI 0.832–0.979)
Nonevident cases	0.124 (95% CI 0.060–0.313)	0.922 (95% CI 0.842–0.975)	0.322 (95% CI 0.183–0.598)	0.976 (95% CI 0.950–0.992)
Specialized participants	0.105 (95% CI 0.043–0.289)	0.799 (95% CI 0.604–0.933)	0.344 (95% CI 0.192–0.628)	0.947 (95% CI 0.890–0.983)
Nonspecialized participants	0.188 (95% CI 0.094–0.430)	0.969 (95% CI 0.843–0.975)	0.337 (95% CI 0.191–0.617)	0.964 (95% CI 0.925–0.988)

NPV improved from 39% to 63%. For the evident cases the sensitivity was 93% before and 97% after the training. The sensitivity for the nonevident (borderline) cases was 74% before and 95%

after the training, while the specificity was 55% before and 38% after. The PPV was 82% and became 80%; the NPV was 44% and improved to 73%.

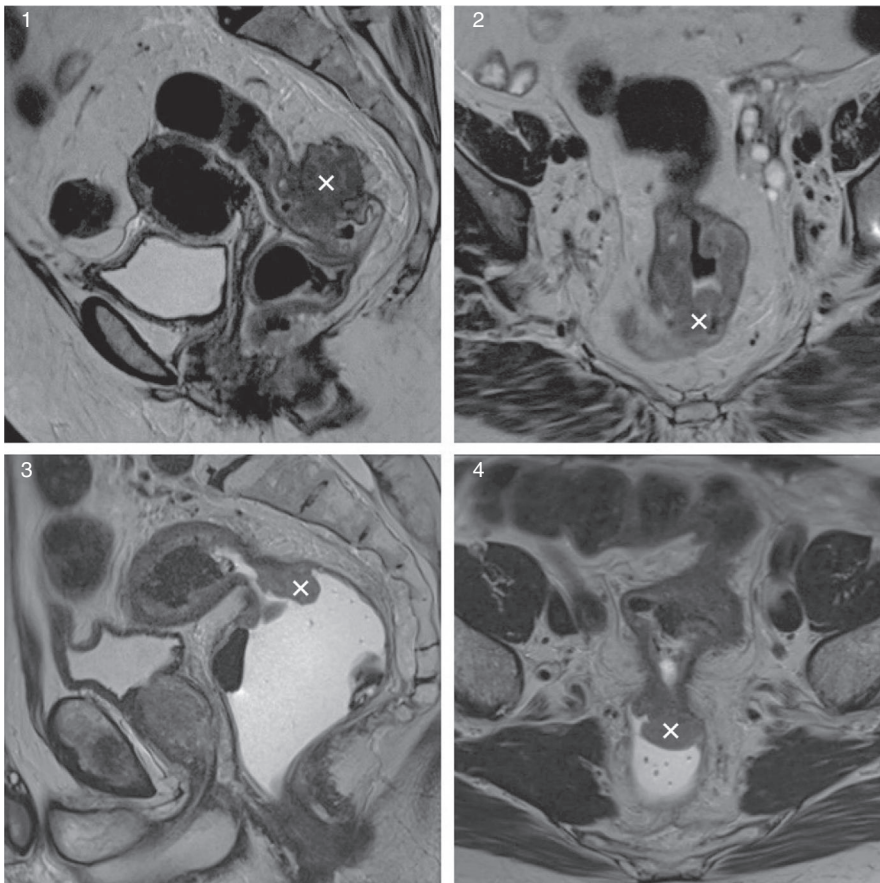
## DISCUSSION

This study, including 86 multidisciplinary participants, demonstrates that the new definition of the rectum is well known but not yet implemented in all MDT meetings 1 year after the updated guidelines were published. The STO was used by 32% of radiologists and 73% of surgeons in their definition of rectal cancer, although these specialists were not always from the same hospitals. More than half of the experts who were in the Delphi consensus meeting were surgeons, possibly explaining this variation [1]. The results of this study show that there is low agreement with the expert reference when a radiological landmark is introduced without further training, but that this can be improved after training (53% vs. 70%,  $p < 0.001$ ). There was no significant difference in the agreement with the expert reference for those who already used the landmark consistently in MDT meetings compared with those who did not. Therefore, implementation of new radiological landmarks should be accompanied by adequate training to ensure an unambiguous assessment.

It is important to emphasize that the Delphi consensus document only addressed the definition of the rectum, without defining rectal cancer. After publication, the new definition of the rectum was immediately incorporated into a modified definition of rectal cancer during an update of the Dutch guidelines in October 2019 [12]. To our knowledge these are the first and only national guidelines to have officially included this definition of the rectum and rectal cancer [10,16].

There is a significant difference in agreement between the evident and the nonevident cases (Table 2), suggesting that variation mainly occurs in classifying the tumours situated around the STO (the 'borderline' cases). The agreement rate for the evident cases was already high before the training, while this significantly improved for the nonevident cases after training. The example used by d'Souza et al. has a clear horizontal sweep; however, this anatomy can be highly variable [12]. A tortuous or elongated rectum, collapsed anatomy (case 7; Figure 2), a dilated ampulla (case 10; Figure 2) or tumours with the distal edge at the level of the STO can increase the difficulty in determining the exact point of the STO. A tortuous rectum was also mentioned by d'Souza et al. as the reason for discrepancies when validating the STO on MRI compared with a surgical specimen [17].

Concerning the accuracy and the ICC in this study, the sensitivity improved (74% vs. 95%) and the PPV barely changed for the nonevident cases (82% vs. 81%). Rectal tumours were less often misdiagnosed as sigmoid tumours after the training. The NPV improved from 44% to 73% for the nonevident cases, but the specificity decreased from 55% to 38%. There were therefore fewer false negatives, but sigmoidal tumours were more often diagnosed as rectal tumours after the training. These tumours were located around the STO and were previously diagnosed as rectal tumours; this group represents the most challenging cases. Also, the training included only three tumours located above the STO, which must be considered.



**FIGURE 2** Clockwise from top left (the tumour is indicated by the cross): (1) sagittal view case 7; (2) axial view case 7 (this case shows the variation in anatomy in case of a collapsed rectum); (3) sagittal view case 10; (4) axial view case 10 (this case shows the change in anatomy in case of a dilated rectum)

The ICC represents the agreement between the ratings of the participants, and can have a value between 0 (no agreement) and 1 (perfect agreement). The ICC single measures were poor or fair before and after the training; however, the average measures were excellent for all groups. This was most likely caused by the large number of participants, with a high chance of outliers that can lower the single measures. The average measures value indicates that the IRR was high before and after the training. This probably suggests that for high reliability, the location of the tumour should be assessed by more than one clinician.

The training improved the overall agreement with the expert reference (53% before and 70% after the training). Radiological training for a higher agreement with the expert reference has previously been described to be of added value for the detection of extramural venous invasion on MRI (MREVI) and the assessment of CT colonography [18–21]. MREVI is a promising prognostic factor in rectal cancer, but can be difficult to assess. Two of the four inexperienced radiologists in a study by Wang et al. received targeted training resulting in a 20% increase in agreement with expert reference [18]. A computer-based self-training module also showed improvement in lesion sensitivity on CT colonography from 74% to 83% ( $p < 0.001$ ) [22]. Liedenbaum et al. indicated that readers obtained equal sensitivity after a training programme to that of experienced readers [21].

Training appears to increase agreement with the expert reference, especially for nonevident cases, eventually leading to an optimization of diagnosis and treatment. During MDT meetings, the radiologist is considered the expert for reviewing imaging. However, it is also important for surgeons to understand the anatomy on images to help determine the optimal treatment and for surgical preparation. Therefore, both surgeons and radiologists were invited to participate. Interestingly, differences in improvement between the various groups were found (Table 2). All groups improved significantly after the training, except for the surgeons. Surgeons had the highest baseline score but seemed to be less ‘trainable’ as they showed the least improvement and had the lowest scores after completing the training. Surgical residents and interns had the lowest baseline score, but improved the most. The surgical residents, interns and PAs also showed significantly increased self-assessment scores when subjectively estimating their ability to assess an MRI scan. These results could therefore be used as a rationale to include the assessment of imaging during surgical training.

## Limitations

For proper assessment of an MRI scan the full scan is preferable, but this study only included one sagittal and axial image of the MRI scan to make it practical for all participants. It was ensured that both the tumour and the STO were visible, and if the tumour was difficult to recognize it was indicated with an arrow. Additionally, the selection of cases with a certain level of difficulty, increasing the chance of disagreement, will have influenced the results. Furthermore, the

collaborators had to score 20 different tumours below, on or above the STO. These three categories are not used in daily practice, but were chosen to examine the height of the tumour in more detail. Also, an expert-based reference assessment was used to determine agreement, while variability among experts is possible. Moreover, appropriate treatment does not only depend on the location relative to the STO; other characteristics may contribute. For example, a sigmoid tumour with growth into the presacral fascia might still benefit from neoadjuvant treatment.

## Further dissemination

In this study the STO training has been provided to members of the Dutch Snapshot Research Group. However, due to the significant improvement seen after the training, this training is currently available for all Dutch radiologists, colorectal surgeons and radiological and surgical residents to improve assessment on a national level. This can further be extended internationally; however, to our knowledge, the definition of the rectum based on the STO landmark has only been translated into the definition of a rectal tumour in the Dutch guidelines.

## CONCLUSION

One year after incorporation of the new definition of a rectal tumour into the Dutch colorectal cancer guidelines (the lower border of the tumour is situated below the STO), approximately half of the represented hospitals had implemented the definition into MDT meetings. The baseline agreement with the expert reference was low in determining the tumour with respect to the STO, even among specialists who already used this landmark as their standard definition. These results indicate that new landmarks which are included in national guidelines and are published with only one example are not sufficiently implemented into daily practice. This can be improved with training explaining the new definition with multiple examples. The implementation of such a landmark should be accompanied with adequate training to ensure unambiguous assessment, especially when considering the implications that variable interpretations may have for implementing correct treatment strategies.

## ACKNOWLEDGEMENTS

We acknowledge S. van Dieren, MSc, PhD for advising on the statistical analyses.

## CONFLICT OF INTEREST

None.

## AUTHOR CONTRIBUTIONS

Conceptualization: Hazen, Sluckin, Horsthuis, Lambregts, Beets-Tan, Tanis, Kusters; Methodology: Hazen, Sluckin, Horsthuis, Tanis,




Kusters; Formal analysis and investigation: Hazen, Sluckin; Writing - original draft preparation: Hazen, Sluckin, Kusters; Writing - review and editing: Hazen, Sluckin, Horsthuis, Lambregts, Beets-Tan, Tanis, Kusters and all participating members of the Dutch Snapshot Research Group; Resources: all participating members of the Dutch Snapshot Research Group; Supervision: Horsthuis, Lambregts, Beets-Tan, Tanis, Kusters.

## DATA AVAILABILITY STATEMENT

The data that support the findings of this study are available from the corresponding author upon reasonable request.

## ORCID

Sanne-Marije J. A. Hazen  <https://orcid.org/0000-0001-8372-1986>

Tania C. Sluckin  <https://orcid.org/0000-0002-5913-2644>

Karin Horsthuis  <https://orcid.org/0000-0001-9699-4561>

Doenja M. J. Lambregts  <https://orcid.org/0000-0003-2990-0099>

Regina G. H. Beets-Tan  <https://orcid.org/0000-0002-8533-5090>

Pieter J. Tanis  <https://orcid.org/0000-0002-3146-3310>

Miranda Kusters  <https://orcid.org/0000-0002-2468-9186>

## REFERENCES

- D'Souza N, de Neree tot Babberich M, Lord A, Shaw A, Abulafi M, Tekkis P, et al. The rectosigmoid problem. *Surg Oncol.* 2018;27(3):521-5.
- D'Souza N, Balyasnikova S, Tudyka V, Lord A, Shaw A, Abulafi M, et al. Variation in landmarks for the rectum: an MRI study. *Colorectal Dis.* 2018;20(10):O304-O9.
- Kapiteijn E, Marijnen CAM, Nagtegaal ID, Putter H, Steup WH, Wiggers T, et al. Preoperative radiotherapy combined with total mesorectal excision for resectable rectal cancer. *N Engl J Med.* 2001;345(9):638-46.
- Fleshman J, Branda M, Sargent DJ, Boller AM, George V, Abbas M, et al. Effect of laparoscopic-assisted resection vs open resection of stage II or III rectal cancer on pathologic outcomes: the ACOSOG Z6051 randomized clinical trial. *JAMA.* 2015;314(13):1346-55.
- Cedermark B, Dahlberg M, Glimelius B, Pahlman L, Rutqvist LE, Wilking N. Improved survival with preoperative radiotherapy in resectable rectal cancer. *N Engl J Med.* 1997;336(14):980-7.
- André T, Boni C, Mounedji-Boudiaf L, Navarro M, Taberno J, Hickish T, et al. Oxaliplatin, fluorouracil, and leucovorin as adjuvant treatment for colon cancer. *N Engl J Med.* 2004;350(23):2343-51.
- Breugom AJ, Swets M, Bosset J-F, Collette L, Sainato A, Cionini L, et al. Adjuvant chemotherapy after preoperative (chemo)radiotherapy and surgery for patients with rectal cancer: a systematic review and meta-analysis of individual patient data. *Lancet Oncol.* 2015;16(2):200-7.
- Glynn-Jones R, Wyrwicz L, Turet E, Brown G, Rödel C, Cervantes A, et al. Rectal cancer: ESMO Clinical Practice Guidelines for diagnosis, treatment and follow-up. *Ann Oncol.* 2018;29(Suppl 4):iv263.
- Hashiguchi Y, Muro K, Saito Y, Ito Y, Ajioka Y, Hamaguchi T, et al. Japanese Society for Cancer of the Colon and Rectum (JSCCR) guidelines 2019 for the treatment of colorectal cancer. *Int J Clin Oncol.* 2020;25(1):1-42.
- You YN, Hardiman KM, Bafford A, Poylin V, Francone TD, Davis K, et al. The American Society of Colon and Rectal Surgeons clinical practice guidelines for the management of rectal cancer. *Dis Colon Rectum.* 2020;63(9):1191-222.
- Moran B, Karandikar S, Geh I. Association of Coloproctology of Great Britain & Ireland (ACPGBI): guidelines for the management of cancer of the colon, rectum and anus (2017) - introduction. *Colorectal Dis.* 2017;19(Suppl 1):6-8.
- D'Souza N, de Neree tot Babberich MPM, d'Hoore A, Turet E, Xynos E, Beets-Tan RGH, et al. Definition of the rectum: an international, expert-based Delphi consensus. *Ann Surg.* 2019;270(6):955-9.
- [https://richtlijndatabase.nl/richtlijn/colorectaal\\_carcinoom\\_crc/diagnostiek\\_bij\\_crc/locoregionale\\_stadi\\_ring\\_rectumcarcinoom\\_bij\\_crc.html](https://richtlijndatabase.nl/richtlijn/colorectaal_carcinoom_crc/diagnostiek_bij_crc/locoregionale_stadi_ring_rectumcarcinoom_bij_crc.html). Accessed 12 January 2021
- Group DSR. Benchmarking recent national practice in rectal cancer treatment with landmark randomized controlled trials. *Colorectal Dis.* 2017;19(6):O219-o31.
- Hallgren KA. Computing Inter-rater reliability for observational data: an overview and tutorial. *Tutor Quant Methods Psychol.* 2012;8(1):23-34.
- Benson AB, Venook AP, Al-Hawary MM, Arain MA, Chen YJ, Ciombor KK, et al. NCCN guidelines insights: rectal cancer, version 6.2020. *J Natl Compr Canc Netw.* 2020;18(7):806-15.
- D'Souza N, Lord A, Shaw A, Patel A, Balyasnikova S, Tudyka V, et al. The sigmoid take-off: an anatomical imaging definition of the rectum validated on specimen analysis. *Eur J Surg Oncol.* 2020;46(9):1668-72.
- Wang S, Li X-T, Zhang X-Y, Sun R-J, Qu Y-H, Zhu H-C, et al. MRI evaluation of extramural vascular invasion by inexperienced radiologists. *Br J Radiol.* 2019;92(1104):20181055.
- Sali L, Delsanto S, Sacchetto D, Correale L, Falchini M, Ferraris A, et al. Computer-based self-training for CT colonography with and without CAD. *Eur Radiol.* 2018;28(11):4783-91.
- Taylor SA, Halligan S, Burling D, Morley S, Bassett P, Atkin W, et al. CT colonography: effect of experience and training on reader performance. *Eur Radiol.* 2004;14(6):1025-33.
- Liedenbaum MH, Bipat S, Bossuyt PMM, Dwarkasing RS, de Haan MC, Jansen RJ, et al. Evaluation of a standardized CT colonography training program for novice readers. *Radiology.* 2011;258(2):477-87.
- Bakker IS, Snijders HS, Wouters MW, Havenga K, Tollenaar R, Wiggers T, et al. High complication rate after low anterior resection for mid and high rectal cancer; results of a population-based study. *Eur J Surg Oncol.* 2014;40(6):692-8.

**How to cite this article:** Hazen S-MJA, Sluckin TC, Horsthuis K, Lambregts DMJ, Beets-Tan RGH, Tanis PJ, et al; the Dutch Snapshot Research Group. Evaluation of the implementation of the sigmoid take-off landmark in the Netherlands. *Colorectal Dis.* 2022;24:292-307. <https://doi.org/10.1111/codi.16005>

## APPENDIX A

## CLASSIFICATIONS OF THE CASES ACCORDING TO THE EXPERT REFERENCE

Case	Above/on/under sigmoid take-off	Rectal tumour/sigmoidal tumour	Evident/nonevident
1	Under	Rectal tumour	Evident
2	Under	Rectal tumour	Evident
3	Under	Rectal tumour	Evident
4	Under	Rectal tumour	Nonevident
5	Under	Rectal tumour	Nonevident
6	Under	Rectal tumour	Evident
7	On	Rectal tumour	Nonevident
8	On	Rectal tumour	Nonevident
9	Under	Rectal tumour	Nonevident
10	Above	Sigmoidal tumour	Nonevident
11	Under	Rectal tumour	Evident
12	Under	Rectal tumour	Evident
13	Under	Rectal tumour	Nonevident
14	Under	Rectal tumour	Evident
15	Above	Sigmoidal tumour	Nonevident
16	Under	Rectal tumour	Evident
17	Under	Rectal tumour	Evident
18	Under	Rectal tumour	Nonevident
19	Above	Sigmoidal tumour	Nonevident
20	On	Rectal tumour	Nonevident

## APPENDIX B

## TRAINING SLIDES

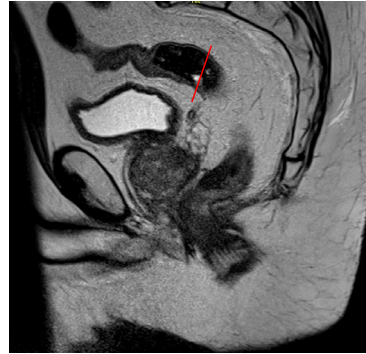

## E-Learning: Sigmoid take-off

## Sigmoid take-off



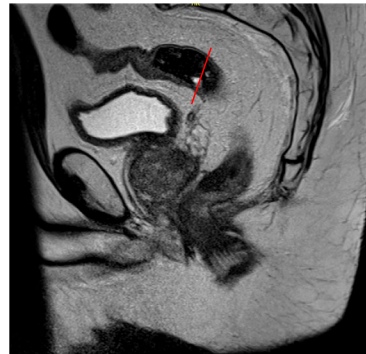- Previously no uniform definition of the rectum
- Clinical relevant for:
  - Indication of (neo)adjuvant therapy
  - Type of resection
  - Preoperative counseling
  - Comparison between studies
- Through a Delphi consensus the sigmoid-take off was chosen as the landmark on MRI to distinguish the rectum from the sigmoid colon



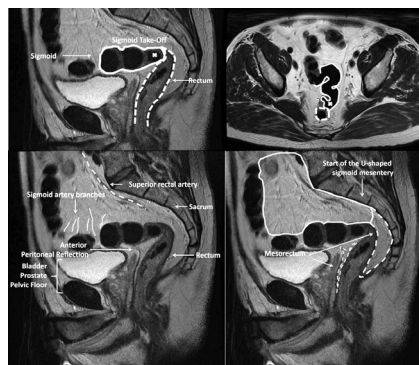
## Sigmoid take-off



- Distinction between:
  - Sigmoid tumour: lower border of the tumour above the take-off
  - Rectal tumour: lower border of the tumour on or under the take-off
- The sigmoid take-off identifies the point where the fixated mesorectum ends, the rectum is no longer fixated to the sacrum, and where the mesocolon becomes mobile.
- This point is visible on MRI as where the sigmoid colon moves away ventrally from the sacrum as seen on the axial plane and/or horizontally as seen on the sagittal plane.



## Sigmoid take-off



Top left: sagittal view of the sigmoid (continuous outline) and rectum (dashed outline). Horizontal sweep of the sigmoid.

Top right: axial view of the sigmoid (continuous outline) and rectum (dashed outline). Ventral projection of the sigmoid, when the mesorectum, tethered to the sacrum, transitions to the mesocolon.

Bottom left: spidery sigmoid arteries supply the sigmoid through its fan-shaped mesocolon. The superior rectal artery (dashed) bifurcates and supplies the rectum.

Bottom right: the u-shaped sigmoid mesocolon

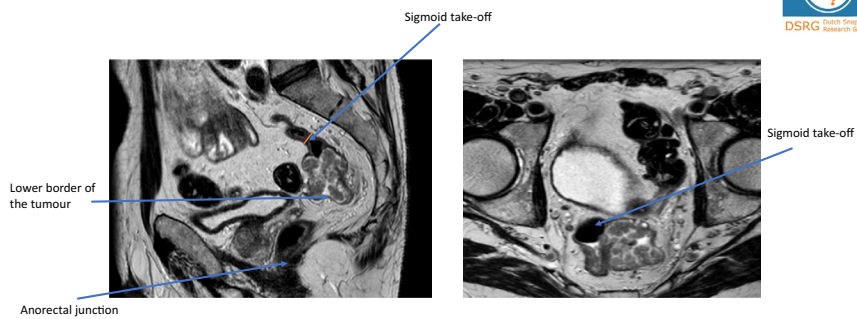
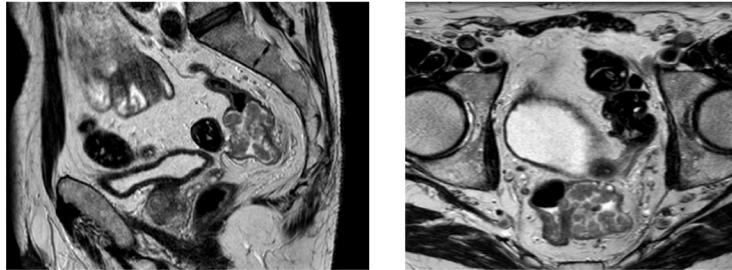
## Example MRIs to practice



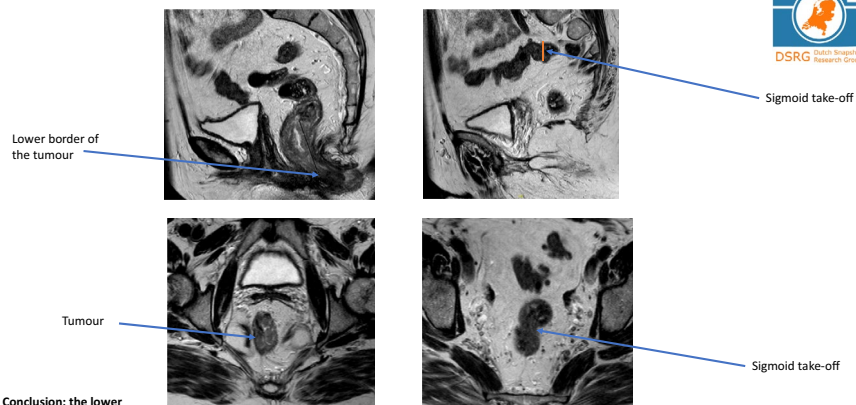
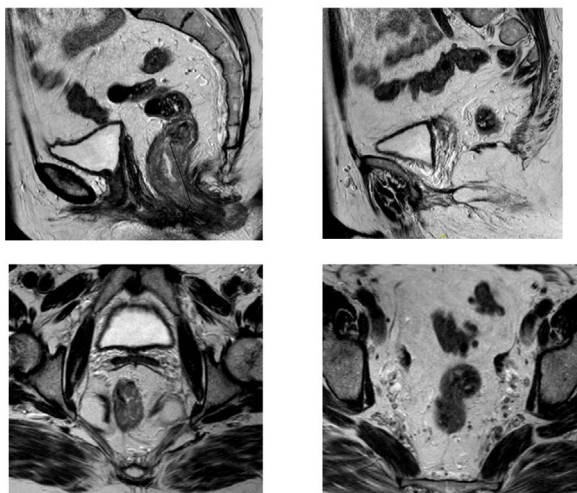
- First MRI → without labels: where is the tumour located and where is the sigmoid take-off?

*Where is the lower border located in relation to the sigmoid take-off?*

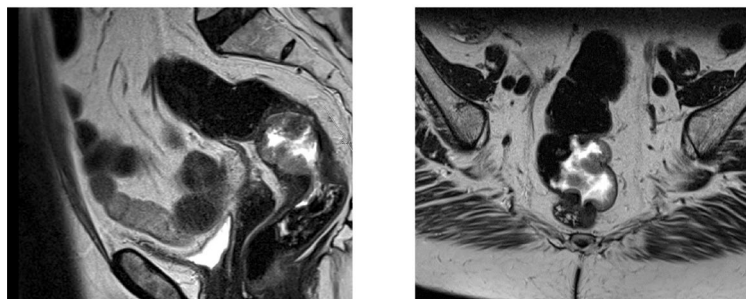
- Second MRI → with labels according to the experts

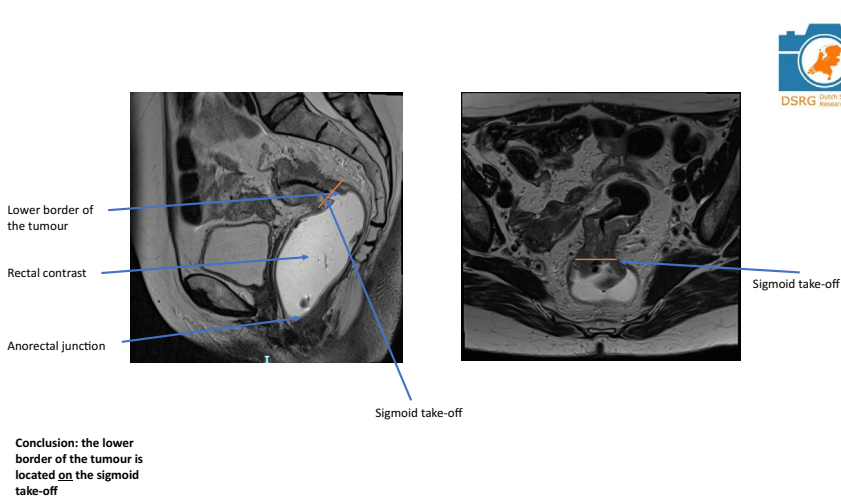
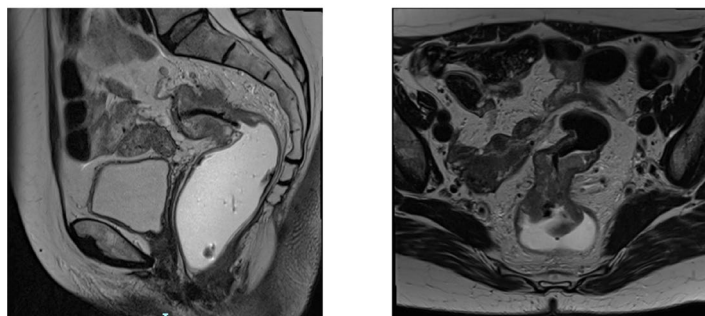
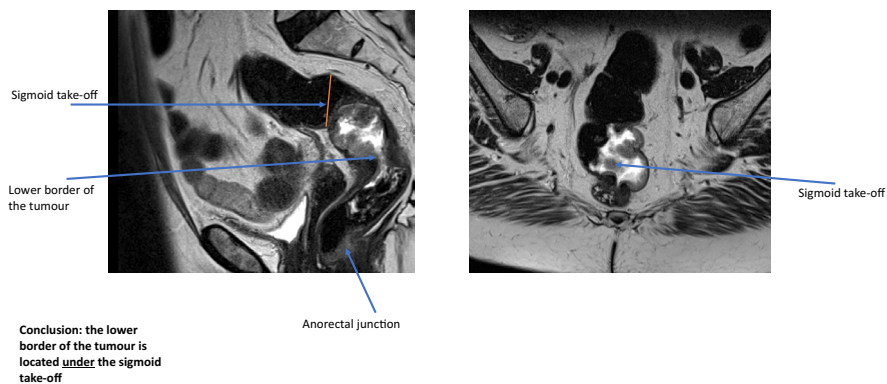


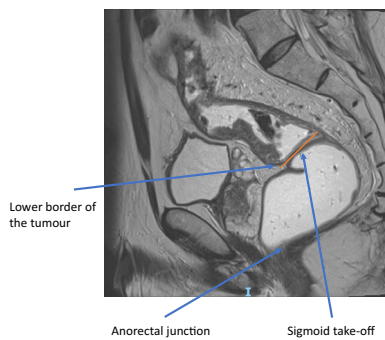
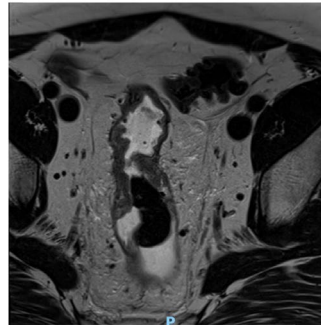
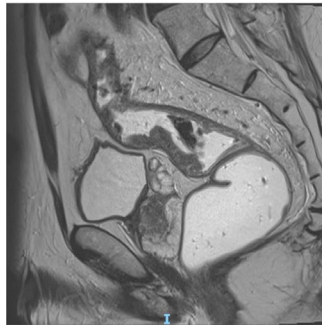**Conclusion: the lower border of the tumour is located under the sigmoid take-off**



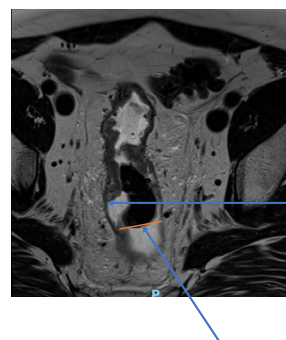
Conclusion: the lower border of the tumour is located under the sigmoid take-off







**Conclusion: the lower border of the tumour is located above the sigmoid take-off**



## APPENDIX C

Anne M. Dinaux, MD, PhD, Department of Surgery, Albert Schweitzer Hospital, Dordrecht, The Netherlands; Bas Lamme, MD, PhD, Department of Surgery, Albert Schweitzer Hospital, Dordrecht, The Netherlands; Gijsbert D. Musters, MD, PhD, Department of Surgery, Albert Schweitzer Hospital, Dordrecht, The Netherlands; Fleur Bangert, MD, Department of Radiology, Alrijne Hospital, Leiden, The Netherlands; Eva Knöps, MD, Department of Surgery, Alrijne Hospital, Leiden, The Netherlands; Sofieke Temmink, MD, Department of Surgery, Alrijne Hospital, Leiden, The Netherlands; Peter A. M. Kint, MD, Department of Radiology, Amphia Hospital, Breda, The Netherlands; Robert R. J. Coebergh van den Braak, MD, PhD, Department of Surgery, Amphia Hospital, Breda, The Netherlands; Puck Schuivens, MD, Department of Surgery, Amphia Hospital, Breda, The Netherlands; Willem A. Bemelman, MD, PhD, Department of Surgery, Amsterdam University Medical Centers, Amsterdam, The Netherlands; Wernard A. A. Borstlap, MD, PhD, Department of Surgery, Amsterdam University Medical Centers, Amsterdam, The Netherlands; Pieter J. Haasnoot, MD, PhD, Department of Surgery, Amsterdam University Medical Centers, Amsterdam, The Netherlands; Roel Hompes, MD, PhD, Department of Surgery, Amsterdam University Medical Centers, Amsterdam, The Netherlands; Jurriaan B. Tuynman, MD, PhD, Department of Surgery, Amsterdam University Medical Centers, Amsterdam, The

Netherlands; Erik J. Mulder, MD, Department of Surgery, Antonius Hospital Sneek, Sneek, The Netherlands; G. Y. M. The, MD, Department of Radiology, Bravis Hospital, Bergen op Zoom and Roosendaal, The Netherlands; Jeroen F. Prette, MD, Department of Radiology, Canisius Wilhelmina Hospital, Nijmegen, The Netherlands; Pepijn Krielen, MD, PhD, Department of Surgery, Canisius Wilhelmina Hospital, Nijmegen, The Netherlands; Joost D. J. Plate, MD, PhD, Department of Surgery, Canisius Wilhelmina Hospital, Nijmegen, The Netherlands; Joost Nederend, MD, PhD, Department of Radiology, Catharina Hospital Eindhoven, Eindhoven, The Netherlands; Stijn Ketelaers, MD, Department of Surgery, Catharina Hospital Eindhoven, Eindhoven, The Netherlands; Stefi Nordkamp, MD, Department of Surgery, Catharina Hospital Eindhoven, Eindhoven, The Netherlands; Shira H. de Bie, MD, Department of Radiology, Deventer Hospital, Deventer, The Netherlands; Jonanne F. Nieuwenhuis, MSc, Department of Surgery, Deventer Hospital, Deventer, The Netherlands; A. Koen Talsma, MD, PhD, Department of Surgery, Deventer Hospital, Deventer, The Netherlands; G. F. A. J. B. van Tilborg, MD, Department of Radiology, Elisabeth Tweesteden Hospital, Tilburg, The Netherlands; Wouter M. Verduin, MD, Department of Surgery, Elisabeth Tweesteden Hospital, Tilburg, The Netherlands; Sander van der Wolk, MD, Department of Radiology, Elkerliek Hospital, Helmond, The Netherlands; Jan M. van Rees, MD, Department of Surgery, Erasmus University Medical Center,

Rotterdam, The Netherlands; Joost Rothbarth, MD, PhD, Department of Surgery, Erasmus University Medical Center, Rotterdam, The Netherlands; E. J. de Groof, MD, PhD, Department of Surgery, Flevo Hospital, Almere, The Netherlands; Jennifer W. Bradshaw, MD, Department of Radiology, Franciscus Gasthuis & Vlietland, Rotterdam, The Netherlands; Marit E. van der Sande, MD, PhD, Department of Surgery, Gerle Hospitals, Apeldoorn, The Netherlands; Edwin S. van der Zaag, MD, PhD, Department of Surgery, Gerle Hospitals, Apeldoorn, The Netherlands; Boudewijn ESchaafsma, MD, PhD, Department of Surgery, Groene Hart Hospital, Gouda, The Netherlands; Fleur I. de Korte, MD, Department of Radiology, Haaglanden Medical Center, Den Haag, The Netherlands; Clementine L. A. Vogelij, Bsc, Department of Surgery, Haaglanden Medical Center, Den Haag, The Netherlands; Annette Zeilstra, MD, Department of Surgery, Haaglanden Medical Center, Den Haag, The Netherlands; Marjolein Ankersmit, MD, PhD, Department of Surgery, Hospital GelderseVallei, Nijmegen, The Netherlands; Bas Frietman, MD, Department of Surgery, Hospital GelderseVallei, Nijmegen, The Netherlands; Sicco J. Braak, MD, PhD, Department of Radiology, Hospital Group Twente, Almelo, The Netherlands; L. S. E. van Egdome, MD, PhD, Department of Surgery, Ikazia Hospital, Rotterdam, The Netherlands; Joost Nonner, MD, Department of Surgery, Ikazia Hospital, Rotterdam, The Netherlands; Amarins T. A. Brandsma, MD, Department of Surgery, Isala Hospital, Zwolle, The Netherlands; Floris B. Poelmann, MD, Department of Surgery, Isala Hospital, Zwolle, The Netherlands; H. L. van Westreenen, MD, PhD, Department of Surgery, Isala Hospital, Zwolle, The Netherlands; Shirin S. Feshtali, MD, Department of Radiology, Leiden University Medical Center, Leiden, The Netherlands; Vera Heesink, MD, Department of Surgery, Maas Hospital Pantein, Beugen, The Netherlands; Stefan H. E. M. Clermonts, MD, PhD, Department of Surgery, Maastricht University Medical Center, Maastricht, The Netherlands; Bas Keizers, MD, Department of Surgery, Martini Hospital, Groningen, The Netherlands; Allard Wijma, MD, Department of Surgery, Martini Hospital, Groningen, The Netherlands; Saskia G. C. van Elderen, MD, Department of Radiology, Maxima Medical Center, Veldhoven, The Netherlands; Esther C. J. Consten, MD, PhD, Department of Surgery, Meander Medical Center, Amersfoort, The Netherlands and Department of Surgery, University Medical Center Groningen, Groningen, The Netherlands; Anna Hogewoning, MD, Department of Surgery, Meander Medical Center, Amersfoort, The Netherlands; Daniela Jou-Valencia, MD, Department of Surgery, Medical Center Leeuwarden, Leeuwarden, The Netherlands; Ida Paulusma, MSc, Department of Surgery, Nij Smellignhe Hospital, Drachten, The Netherlands; Martsje van der Sluis, MSc, Department of Surgery, Nij Smellignhe Hospital, Drachten, The Netherlands; Sjoerd van den Hoek, MD, Department of Surgery, Noord West Hospital Group, Alkmaar, The Netherlands; Nadia A. G. Hakkenbrak, MD, Department of Surgery, Noord West Hospital Group, Alkmaar, The Netherlands; Renée M. Barendse, MD, PhD, Department of Surgery, Onze Lieve Vrouwe Gasthuis, Amsterdam, The Netherlands; Arja. Gerritsen MD, PhD, Department of Surgery, Onze Lieve Vrouwe Gasthuis, Amsterdam, The

Netherlands; Anouk J. M. Rombouts, MD, PhD, Department of Surgery, Radboud University Medical Center, Nijmegen, The Netherlands; Seyed Qaderi, MD, Department of Surgery, Radboud University Medical Center, Nijmegen, The Netherlands; Johannes H. W. de Wilt, MD, PhD, Department of Surgery, Radboud University Medical Center, Nijmegen, The Netherlands; Leonard F. Kroese, MD, PhD, Department of Surgery, Reinier de Graaf Hospital, Delft, The Netherlands; Pim B. Olthof, MD, PhD, Department of Surgery, Reinier de Graaf Hospital, Delft, The Netherlands; Herman J. A. Zandvoort, MD, PhD, Department of Radiology, Rijnstate Hospital, Arnhem, The Netherlands; Kemal Dogan, MD, PhD, Department of Surgery, Rijnstate Hospital, Arnhem, The Netherlands; Ernst Jan Spillenaar Bilgen, MD, PhD, Department of Surgery, Rijnstate Hospital, Arnhem, The Netherlands; Sjirk W. van der Burg, MD, Department of Surgery, Rode Kruis Hospital, Beverwijk, The Netherlands; Anouk Emmen, MD, Department of Surgery, Rode Kruis Hospital, Beverwijk, The Netherlands; Paul P. van Westerveld, MD, Department of Radiology, Slingeland Hospital, Doetinchem, The Netherlands; Sylvia Kok, MSc, Department of Surgery, Slingeland Hospital, Doetinchem, The Netherlands; A. E. Pasma-Bouma, MD, PhD, Department of Surgery, Slingeland Hospital, Doetinchem, The Netherlands; Jeroen Tielbeek, MD, PhD, Department of Radiology, Spaarne Gasthuis, Haarlem, The Netherlands; Tyche Derksen, MD, Department of Surgery, Spaarne Gasthuis, Haarlem, The Netherlands; Victor van Woerden, MD, PhD, Department of Surgery, Spaarne Gasthuis, Haarlem, The Netherlands; Robin D. Blok, MD, PhD, Department of Surgery, Tergooi Hospital, Hilversum, The Netherlands; Jacqueline Jonkers, MSc, Department of Surgery, Treant Zorggroep, Emmen, Hogeveen, Stadskanaal, The Netherlands; Robbert J. de Haas, MD, PhD, Department of Radiology, University Medical Center Groningen, Groningen, The Netherlands; Ilsaen. S. Bakker, MD, PhD, Department of Surgery, University Medical Center Groningen, Groningen, The Netherlands; E. A. Feitsma, MD, Department of Surgery, University Medical Center Groningen, Groningen, The Netherlands; Edgar J. B. Furnee, MD, PhD, Department of Surgery, University Medical Center Groningen, Groningen, The Netherlands; Thijs Burghgraef, MD, Department of Surgery, Utrecht University Medical Center, Utrecht, The Netherlands; S. T. van Vugt, MD, Department of Surgery, Wilhelmina Hospital Assen, Assen, The Netherlands; Frank den Boer, MD, PhD, Department of Surgery, Zaans Medical Center, Zaandam, The Netherlands; Maaïke Corver, MSc, Department of Surgery, Zaans Medical Center, Zaandam, The Netherlands; Sifrid Hendrickx, MD, Department of Radiology, ZorgSaam Hospital, Terneuzen, The Netherlands; Dietrich J. L. de Mey, MD, Department of Surgery, ZorgSaam Hospital, Terneuzen, The Netherlands; Roy F. A. Vliegen, MD, PhD, Department of Radiology, Zuyderland Medical Center, Sittard-Geleen, The Netherlands; Evert-Jan Boerma, MD, PhD, Department of Surgery, Zuyderland Medical Center, Sittard-Geleen, The Netherlands; Ingrid Poodt, MD, PhD, Department of Surgery, Zuyderland Medical Center, Sittard-Geleen, The Netherlands; Milou H. Martens, MD, PhD, Department of Surgery, Zuyderland Medical Center, Sittard-Geleen, The Netherlands.